

# Eosinophils and IL-33 Perpetuate Chronic Inflammation and Fibrosis in a Pediatric Population with Stricture Crohn's Ileitis

Joanne C. Masterson, PhD,<sup>\*,†,‡</sup> Kelley E. Capocelli, MD,<sup>‡,§</sup> Lindsay Hosford, BA,<sup>\*,†,‡</sup> Kathryn Biette, BA,<sup>\*,†,‡</sup> Eóin N. McNamee, PhD,<sup>†,‡,||</sup> Edwin F. de Zoeten, MD, PhD,<sup>\*,†,‡</sup> Rachel Harris, BA,<sup>\*,†,‡</sup> Shahan D. Fernando, MD,<sup>\*,†,‡</sup> Paul Jedlicka, MD,<sup>‡,§</sup> Cheryl Protheroe, BA,<sup>¶</sup> James J. Lee, PhD,<sup>¶</sup> and Glenn T. Furuta, MD<sup>\*,†,‡</sup>

**Background:** Fibrostenosis and stricture are well-recognized endpoints in Crohn's disease (CD). We hypothesized that stricturing CD is characterized by eosinophilia and epithelial IL-33. We proposed that eosinophil exposure to IL-33 would perpetuate inflammatory chronicity and subsequent fibrostenosis.

**Methods:** We performed a retrospective study of 74 children with inflammatory and stricturing ileal CD comparing clinicopathological features to immunohistochemical measures of eosinophilia and IL-33. To scrutinize eosinophil patterns, we developed a novel eosinophil peroxidase score encompassing number, distribution, and degranulation. Human eosinophils and intestinal fibroblasts were cultured with IL-33 and IL-13, and inflammatory and remodeling parameters were assessed. Antieosinophil therapy was also administered to the Crohn's-like ileitis model (SAMP1/SkuSlc).

**Results:** Our novel eosinophil peroxidase score was more sensitive than H&E staining, revealing significant differences in eosinophil patterns, comparing inflammatory and stricturing pediatric CD. A significant relationship between ileal eosinophilia and complicated clinical/histopathological phenotype including fibrosis was determined. IL-33 induced significant eosinophil peroxidase secretion and IL-13 production. Exposure to eosinophils in the presence of IL-33, "primed" fibroblasts to increase proinflammatory cytokines (TNF- $\alpha$ , IL-1 $\beta$ , and IL-6), eosinophil-associated chemokines (CCL24 and CCL26), and IL-13R $\alpha$ 2 production. Production of fibrogenic molecules (collagen 1A2, fibronectin, and periostin) increased after exposure of "primed" fibroblasts to IL-13. Epithelial-IL-33 was increased in pediatric Crohn's ileitis and strongly associated with clinical and histopathological activity, ileal eosinophilia, and complicated fibrostenotic disease. SAMP1/SkuSlc eosinophil-targeted treatment resulted in significant improvements in inflammation and remodeling.

**Conclusions:** Our study of specimens from pediatric patients with ileal CD linked eosinophil patterns and IL-33 to fibrosis and suggested that these may contribute to the perpetuation of inflammation and subsequent stricture in pediatric CD.

(*Inflamm Bowel Dis* 2015;21:2429–2440)

**Key Words:** pediatric Crohn's disease, eosinophil, fibrosis, stricture

The underlying pathogenesis of Crohn's disease (CD) relates to the complex interactions between genetic, immunologic, and environmental factors. In some cases, chronic inflammation leads to stricture formation and surgical resection of diseased tissue.

Although not all patients develop intestinal strictures, ileal location and duration of disease pose specific risks.<sup>1</sup> In fact, the cumulative incidence of stricturing disease has been reported as 27% at 5 years and 38% at 10 years.<sup>2</sup> Although certain similarities

Supplemental digital content is available for this article. Direct URL citations appear in the printed text and are provided in the HTML and PDF versions of this article on the journal's Web site ([www.ibdjournal.org](http://www.ibdjournal.org)).

Received for publication April 3, 2015; Accepted May 13, 2015.

From the \*Section of Pediatric Gastroenterology, Hepatology and Nutrition, Gastrointestinal Eosinophilic Diseases Program, Department of Pediatrics and Digestive Health Institute, Children's Hospital Colorado, Aurora, Colorado; †Department of Medicine, Mucosal Inflammation Program, University of Colorado School of Medicine, Aurora, Colorado; ‡University of Colorado School of Medicine, Aurora, Colorado; §Department of Pathology, University of Colorado School of Medicine, Aurora, Colorado; ||Department of Anesthesiology, University of Colorado School of Medicine, Aurora, Colorado; and ¶Department of Biochemistry and Molecular Biology, Mayo Clinic Scottsdale, Azusa, California.

Supported by grants from the United States National Institutes of Health (R01-DK62245 and K24-DK 100303) (G.T.F.), and (R01-HL065228 and K26-RR0109709) (J.J.L.), (NIH/NCRN Colorado CTSI Grant Number UL1 RR025780) (J.C.M.) were sources of funding used in the performance of studies including data analysis and manuscript preparation. Grants from Crohn's and Colitis Foundation of America (#3760 & #3047 JCM, #2570195 EMcN), the North American Society for Pediatric Gastroenterology Hepatology and Nutrition (J.C.M.), the American Partnership for Eosinophilic Disorders (J.C.M.), the Mayo Foundation for Medical Education and Research (J.J.L.) were the sources of funding used in the performance of studies including data analysis and manuscript preparation.

The authors have no conflict of interest to disclose.

Reprints: Joanne C. Masterson, PhD, 12700 East 19th Avenue, C226, Aurora, CO 80045 (e-mail: [joanne.masterson@ucdenver.edu](mailto:joanne.masterson@ucdenver.edu)).

Copyright © 2015 Crohn's & Colitis Foundation of America, Inc.

DOI 10.1097/MIB.0000000000000512

Published online 25 July 2015.

exist between pediatric and adult onset disease, pediatric disease is distinct with more extensive and rapidly progressing pathology.<sup>3</sup> Thus, studies focusing specifically on pediatric patients are of great value to gain a better understanding of cause and improved treatments or preventions. Without an exact understanding of the underlying pathogenesis of stricturing disease, the identification of biomarkers, therapeutic targets, and thus Food and Drug Administration–approved treatments remains undiscovered.

Previous studies link CD-related strictures with a number of different cell types including fibroblasts and eosinophils. With respect to eosinophils, a large body of evidence supports their role in tissue remodeling and fibrosis. For instance, eosinophils and eosinophil-derived products induced the activation of fibroblasts *in vitro*, resulting in fibroblast proliferation, collagen gel contraction, and production of fibrogenic molecules, remodeling proteases, cytokines, and chemokines.<sup>4–6</sup> However, to date, no study has examined the relationship between eosinophil patterns in stricturing pediatric CD compared with those with inflammatory pediatric CD. In addition, IL-33 has not been examined comparing stricturing to inflammatory pediatric CD populations. Using a mouse model of CD, others and we previously reported the significant association of eosinophils with mouse ileitis and identified their potential as a novel therapeutic target.<sup>7,8</sup> Because these results provided support for a clinically relevant role for eosinophils in fibrotic CD and because of the identified role of eosinophils in other fibrotic diseases, we wondered whether eosinophil patterns were different in complicated pediatric CD such as stricturing disease compared with inflammatory CD. To address this, we hypothesized that eosinophils were associated with strictured CD in children and that the profibrogenic cytokines, IL-33 and IL-13, stimulated a remodeling response from human eosinophils and intestinal fibroblasts.

## METHODS

### Assessment of Antieosinophil Treatment in Mouse Ileitis

Original SAMP1 strain of the mouse model of Crohn's-like ileitis, SAMP1/SkuSlc female mice 4 to 10 weeks of age, were purchased from Japan SLC (Hamamatsu, Japan).<sup>9</sup> Mice were maintained under specific pathogen-free conditions with ad libitum access to food and water. Anti-CCR3 rat anti-mouse MAb 6S2-19-4 and monoclonal antibody specific for interleukin-5 (TRFK-5; Cayman Chemical, Ann Arbor, MI) both selectively deplete murine eosinophils.<sup>7,10,11</sup> Experimental animals were injected intraperitoneally with 200  $\mu$ g of TRFK-5 antibody, 200  $\mu$ g of anti-CCR3 and 200  $\mu$ g of TRFK-5 antibodies once weekly from 20 to 30 weeks of age and killed 24 hours after final administration. Inflamed control mice were treated intraperitoneally with a nonspecific isotype control antibody with equal dose and duration. The last 10 cm of the ileum was removed, processed, and scored by a pathologist blinded to the experimental conditions (P.J.) as previously described.<sup>7,12</sup>

Briefly, 3 histological parameters were assessed with equal weight for each parameter: (1) active inflammation (granulocytes), (2) chronic inflammation (lymphoplasmacytic infiltrates), and (3) villus distortion (architectural disruption, separation of villi, crypts, and muscularis). Infiltrating eosinophils were identified by immunostaining with rat anti-mouse major basic protein monoclonal antibody (Clone MT-14.7) and quantified as previously described.<sup>7</sup> Ileal sections were stained with periodic acid–Schiff, and goblet cells were quantified as previously described as a measure of remodeling.<sup>7</sup> The University of Colorado School of Medicine Institutional Animal Care and Use Committee approved these studies.

### Subject Selection

A retrospective chart review was performed of patients who were evaluated in the Digestive Health Institute, Section of Pediatric Gastroenterology, Hepatology, and Nutrition at the Children's Hospital Colorado from 2002 to 2011 who had received a diagnosis of CD and had undergone surgical resection (stricturing) or biopsy (inflammatory) of the terminal ileum. Subjects were excluded from this analysis if they had incomplete treatment records. Based on review of the clinical record, subjects were subdivided into either stricturing or nonstricturing ileal disease. Subjects were defined as follows: stricturing CD subjects exhibited symptoms and radiological features consistent with partial obstruction that lead to surgical resection; inflammatory CD subjects had symptoms and clinical evidence of inflammation (laboratories and/or radiographs) without evidence of obstruction; and control subjects had symptoms of gastrointestinal dysfunction, no clinical evidence of inflammation (laboratories and/or radiographs) and normal ileal mucosa. Patients were considered under CD treatment if they were prescribed either 5-aminosalicylates, corticosteroids, immunomodulators, biologic therapies, or antibiotics alone or in combination. Clinical features recorded included location(s) of activity, previous treatments, ESR, CRP, and HgB units and calculation of Pediatric Crohn's Disease Activity Index (PCDAI) (Table 1).<sup>13</sup>

### Human Subject Specimen Histological Assessments

To allow for equal comparison between biopsies and full thickness resected tissues, all histological assessments were performed on mucosal tissue alone and not on deeper resected tissues. Hematoxylin and Eosin (H&E)–stained ileal tissue sections were assessed by board certified pathologist (K.E.C.) for (1) pathological activity (mild active, mild, moderate, or severe chronic active); (2) eosinophil numbers (mean of 5 random high powered fields [HPF] and peak number counted in single most densely inflamed HPF at  $\times 40$  magnification field size 0.26 mm<sup>2</sup>, data presented as mean  $\pm$  range); and (3) lamina propria fibrosis (mild, loose collagen matrix fibrils; moderate, condensed collagen matrix fibrils; or severe, substantially condensed collagen matrix fibrils) (see Fig. A, Supplemental Digital Content 1, <http://links.lww.com/IBD/B2>). Measurement of lamina propria fibrosis was also performed on Masson's Trichrome stained tissue sections.

**TABLE 1.** Clinical Characteristics of Study Subjects

	Control	Inflammatory	Stricturing
Number (n)	39	17	18
Sex (% male)	44	59	67
Age range (median), yr	2–17 (14)	6–17 (14)	8–18 (14)
Disease duration, mo	NA	8.0 ± 2.9	11.3 ± 2.5
ESR, mm/h	10.0 ± 1.7	32.3 ± 6.7	35.7 ± 6.8
CRP, mg/dL	0.5 ± 0.04	6.2 ± 3.7	9.3 ± 2.1
Hgb, g/dL	13.6 ± 0.4	12.0 ± 0.4	11.4 ± 0.5
Previous treatments	Corticosteroid: 0 5-ASA: 0 Immunomodulator: 0 Biologic: 0 Antibiotic: 0	Corticosteroid: 6 5-ASA: 4 Immunomodulator: 6 Biologic: 1 Antibiotic: 5	Corticosteroid: 15 5-ASA: 4 Immunomodulator: 17 Biologic: 4 Antibiotic: 2
PCDAI	NA	35.2 ± 1.9	37.6 ± 2.3

All values mean ± SEM.

No statistical difference between inflammatory and stricturing disease was obtained.

Eosinophil peroxidase (EPX) immunostaining was completed to determine the pattern of eosinophils within tissue specimens. Briefly, each section underwent staining with a monoclonal antibody for EPX (hybridoma MM25-82.2.1) as previously described.<sup>11,14</sup> Slides were assessed for eosinophil patchiness/localization, degranulation, and intact eosinophil numbers to determine an ileal EPX index adapted from that previously described (see Table, Supplemental Digital Content 2, <http://links.lww.com/IBD/B3> and Fig. B, Supplemental Digital Content 1, <http://links.lww.com/IBD/B2>).<sup>14</sup> Priority factors were assigned based on those indices that gave the greatest and the least differences when comparing inflammatory to stricturing specimens allowing stratification of these 2 disease types. On this basis, priorities were assigned to patchiness/localization (priority score: 4), average numbers of eosinophil infiltrating the tissues (priority score: 3), peak eosinophil number infiltrating the tissue (priority score: 2), and degranulation (priority score: 1). Tissue sections were assessed independently and in a blinded manner by a pathologist (K.E.C.) and 2 other research investigators (J.C.M. and L.H.).

Immunostaining was completed for interleukin-33 (polyclonal goat anti-IL-33; R&D Systems, Minneapolis, MN). Slides were assessed for IL-33 staining as follows: none: score 0, present in epithelial cells: score 1, or increased numbers of/presence in epithelial cells: score 2. IL-33–stained tissue sections were assessed independently by 3 research investigators (L.H., R.H., and S.D.F.) blinded to specimen demographics. The Institutional Review Board at the University of Colorado (COMIRB) approved this study.

### Human Eosinophil Isolation

Human eosinophils were isolated from healthy volunteers. Briefly, white blood cells were isolated from whole blood and

anticoagulated with 5% citrate buffer. Plasma was removed after centrifugation. Red blood cells were pelleted from leukocytes using 6% dextran/0.9% saline sedimentation (Fluka; Sigma, St. Louis, MO). Granulocytes were isolated from discontinuous Percol gradients (42% and 51%) (Sigma), and monocytes discarded. Residual erythrocytes were lysed with ice-cold water, and the remaining cells were washed. Eosinophils were purified by negative selection using anti-CD16 and anti-CD14 MACS microbeads and AutoMACS separation (Miltenyi, Auburn, CA). Eosinophils were >95% pure as assessed by fast green (4%). The Institutional Review Board at the University of Colorado (COMIRB) approved this study.

### Assessment of Eosinophil Activation by IL-33

Viable single-cell suspensions were subjected to culture in the presence or absence of 100 ng/mL IL-33 (R&D Systems) for 3 hours. Cells were subjected to flow cytometric analysis with FITC-labeled anti-ST2 or isotype control antibodies (MBL International, Woburn, MA). EPX release into cell supernatants was quantified as a marker of eosinophil activation and granule protein release by peroxidase assay, modified from that previously described.<sup>15</sup> Eosinophils were also pelleted by centrifugation and harvested for electron microscopic analysis in glutaraldehyde fixative as previously described<sup>16</sup> or harvested for total cell RNA isolation with RNeasy Mini Kits (Qiagen, Valencia, CA). Taqman gene expression assays (Applied Biosystems, Foster City, CA) were performed on whole-cell RNA, processed as previously described.<sup>11</sup> Data were normalized to 18S and calculated as Relative Expression ( $2^{-\Delta\Delta Ct}$ ).

### Eosinophil and 18Co Fibroblast Coculture

Intestinal myofibroblasts (18Co-ATCC) were cultured as previously described<sup>4</sup> in the presence of freshly isolated

eosinophils at a ratio of 1:1. After 24 or 48 hours of coculture, eosinophils were completely removed and 18Co cells harvested for total cell RNA isolation with RNeasy Mini Kits (Qiagen). For IL-13 stimulation experiments, 18Co cells were cocultured with eosinophils for 48 hours, eosinophils were removed, and 18Co cells were returned to culture in the presence of IL-13 (100 ng/mL; R&D Systems) for an additional 72 hours at which point 18Cos were harvested for total cell RNA isolation with RNeasy Mini Kits (Qiagen).

## Statistical Analyses

Statistical analyses of data outcomes were performed by Mann–Whitney U test, 1-way analysis of variance (Kruskal Wallis) test with Dunn's correction for multiple comparisons, 1-way analysis of variance (Newman–Keuls) test, Spearman rank correlation test, and Student's *t* test where appropriate. Data are expressed as mean  $\pm$  SEM. A *P* value of  $\leq 0.05$  was considered as statistical significance although in some cases, higher levels of significance are noted and described in the figure legends where applicable (\**P*  $\leq 0.05$ , \*\**P*  $\leq 0.01$ , \*\*\**P*  $\leq 0.001$ ).

## RESULTS

### Eosinophil Targeted Therapies Diminished Chronic Inflammation and Remodeling in a Mouse Model of Crohn's-like Ileitis

To examine the causative effects of eosinophils on tissue remodeling, the SAMP1/SkuSlc mouse model of Crohn's-like disease was treated with eosinophil-targeting antibodies (TRFK-5 or anti-CCR3 and TRFK-5 in combination). A significant improvement in overall inflammation and tissue architecture was determined by examining H&E-stained ileal tissue sections ( $14.8 \pm 1.8$  versus  $4.6 \pm 0.5$ ; *P* < 0.001 versus  $4.7 \pm 1.7$  total inflammatory score; *P* < 0.01) (see Fig. A, Supplemental Digital Content 3, <http://links.lww.com/IBD/B4>). As expected, treatment with both antibody regimens led to a significant reduction in ileal tissue eosinophils as quantified on major basic protein–stained sections ( $200 \pm 22$  versus  $82 \pm 14$ ; *P* < 0.01 versus  $46 \pm 3$  eosinophils/HPF; *P* < 0.001) (see Fig. B, Supplemental Digital Content 3, <http://links.lww.com/IBD/B4>). As a measure of remodeling, goblet cell hyperplasia assessed by periodic acid–Schiff staining was significantly decreased in these anti-eosinophil–treated mice compared with age-matched immunoglobulin G–treated controls ( $30 \pm 3$  versus  $13 \pm 1$ ; *P* < 0.001 versus  $11 \pm 1$  percent goblet cells per villus; *P* < 0.001) (see Fig. C, Supplemental Digital Content 3, <http://links.lww.com/IBD/B4>).

### Eosinophil Mucosal Distribution Pattern Differentiates Stricturing from Nonstricturing Pediatric Ileal CD

Next, we determined whether any histopathological features present in the mucosal surface of clinical specimens from pediatric subjects permitted the distinction of inflammatory from

stricturing CD. Clinical characteristics of stricturing CD subjects (*n* = 18), inflammatory Crohn's subjects (*n* = 17), and control subjects (*n* = 39) are presented in Table 1. Subjects were included in this study who were both treatment naive and those undergoing medical treatments for CD (5-aminosalicylates, corticosteroids, immunomodulators, biologic therapies, or antibiotics alone or in combination). No statistical differences were identified between stricturing and inflammatory CD subjects when comparing mean disease duration and laboratory markers of inflammation (ESR, CRP, and HgB) (Table 1). We next determined whether the number of eosinophils, as traditionally counted on H&E-stained tissues were able to provide distinguishing histological features of these 2 phenotypes. Whereas peak eosinophil counts, as measured by H&E, were increased in inflammatory CD compared with control subjects (*P* < 0.001), they were not significantly increased comparing control subjects to stricturing CD specimens (Fig. 1A, C–E).

On H&E staining, the tinctural features of eosinophils and their granules, in the context of an inflamed mucosa, can make enumeration challenging. Based on this, we questioned whether a more comprehensive assessment of mucosal eosinophil patterns might be beneficial. To address this, we took advantage of our previously developed EPX immunohistochemical staining protocol using this on these ileal tissue specimens. Results from this more sensitive and specific staining could now identify a significant increase in peak eosinophil number comparing stricturing CD specimens to control subjects (*P* < 0.001) (Fig. 1B–E).

To further address this difference in sensitivity between H&E and EPX analysis, a 4-point EPX immunohistochemistry-based indexed scoring system was adapted from our previous work<sup>14</sup> to better characterize eosinophil patterns in the ileal mucosa of stricturing and inflammatory CD specimens (Table 1). EPX scoring analysis revealed a significant increase in eosinophil burden when comparing controls ( $12.97 \pm 0.54$ ; EPX-score) with inflammatory ( $16.64 \pm 0.97$ ; *P* < 0.01) to stricturing CD specimens ( $19.61 \pm 0.9$ ; *P* < 0.001) (Fig. 2A). In contrast to using just peak eosinophil numbers (Fig. 2D), a significant increase in eosinophil pattern as assessed by total EPX score (patchiness/distribution, degranulation and numbers combined) was captured in the stricturing CD specimens as compared with inflammatory CD (*P* < 0.05) (Fig. 2A). Further dissection of differences between inflammatory and structuring CD mucosal eosinophilia revealed differences in patchiness or distribution/localization of eosinophils ( $7.12 \pm 0.44$  versus  $5.52 \pm 0.46$ ; *P* < 0.05, stricturing versus inflammatory) (Fig. 2B) and average number of eosinophils counted across 5 fields of view ( $6.92 \pm 0.34$  versus  $6.06 \pm 0.32$ ; stricturing versus inflammatory) (Fig. 2E). Neither peak number of eosinophils nor degranulation could distinguish between stricturing and inflammatory CD specimens (Fig. 2C, D). Analysis of tissue from treatment-naive subjects showed similar patterns; eosinophil EPX-score was increased in stricturing and inflammatory CD subjects compared with control subjects (see Fig. C, Supplemental Digital Content 4, <http://links.lww.com/IBD/B5>).

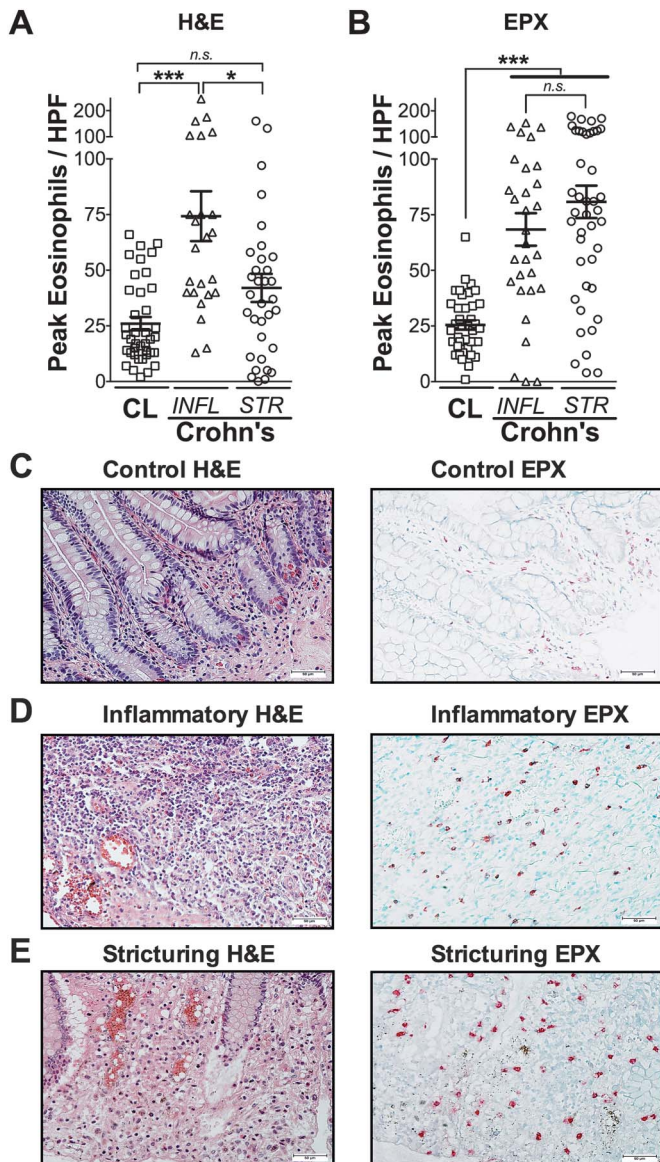


FIGURE 1. Eosinophil patterns are distinguishable between mucosa of inflammatory and stricturing CD. Peak numbers of eosinophils were enumerated in (A) H&E and (B) EPX-stained ileal tissues from patients with CD. Subjects were divided into those with strictures (STR) and those without strictures that had inflammatory CD (INFL). Representative photomicrographs comparing H&E to EPX-stained tissues from control (CL), inflammatory, and stricturing Crohn's-ileia (A-C). Scale bars represent 50  $\mu$ M. Data are expressed as mean  $\pm$  SEM. Statistical significance was assessed by 1-way analysis of variance with Newman-Keuls multiple comparisons test. \* $P \leq 0.05$ , \*\*\* $P \leq 0.001$ .

### Ileal Eosinophilia Correlates with Clinicopathological Features of Pediatric CD

To address the potential association of eosinophils with disease activity, we next correlated the peak number of eosinophils as identified by EPX staining with the PCDAI and

histological features of chronicity and fibrosis. To exclude any potential treatment-effect bias, only treatment-naive specimens were examined. This comparison revealed a highly significant relationship between the peak numbers of eosinophils/HPF and PCDAI ( $r = 0.68$ ,  $P < 0.0001$ ; Fig. 2F). In addition, a highly significant association was identified between eosinophilia and histological chronicity ( $r = 0.76$ ,  $P < 0.0001$ ; Fig. 2G) and fibrosis ( $r = 0.68$ ,  $P < 0.0001$ ; Fig. 2H). The relationship between eosinophilia and fibrosis was also confirmed when examining fibrosis assessed by Masson's Trichrome stain ( $r = 0.33$ ,  $P < 0.01$ ). Together, these results indicate that mucosal eosinophilia is associated with chronicity and complications in pediatric Crohn's ileitis, and that detailed analysis of mucosal eosinophil patterns provides significant benefit in clinically and histologically characterizing inflammatory versus stricturing pediatric CD.

### Eosinophils Are Activated by IL-33 and Prime Intestinal Fibroblasts in the Perpetuation of Eosinophil Recruitment and Exacerbated Fibrosis Through IL-13

We next took a reductionist approach to determine the impact of eosinophils in intestinal fibrosis. Based on previous work suggesting a role for IL-33 in eosinophil and fibrosis-related diseases, we first determined the ability of IL-33 to induce eosinophil degranulation and the production of fibrogenic cytokines associated with inflammatory bowel disease (IBD) such as IL-13.<sup>17</sup> We first confirmed that human eosinophils expressed the cognate IL-33 receptor ST2 by flow cytometry; similar to previously published studies, we show that  $18.3\% \pm 6.9\%$  of resting human eosinophils express ST2 ( $n = 3$  donors). Next, we found that the exposure of human eosinophils to IL-33 resulted in eosinophil activation observed by electron micrograph, including membrane ruffling and reversal of granule staining consistent with degranulation (Fig. 3A). IL-33 stimulated eosinophils also resulted in significant release of EPX compared with controls, as captured by immunofluorescence assay (Fig. 3B). Finally, we examined the ability of IL-33 to induce human eosinophil-derived fibrogenic IL-13, as had previously been demonstrated for mouse eosinophils. These results demonstrated a significant increase in IL-13 mRNA synthesis (19-fold;  $P < 0.01$ ) (Fig. 3C).

To further determine the downstream impact of IL-33-stimulated eosinophils, we examined whether these activated leukocytes could induce a proinflammatory response from intestinal fibroblasts (Fig. 4). Our results showed that coculture of IL-33-stimulated eosinophils with intestinal fibroblasts led to increased production of a number of inflammatory (TNF- $\alpha$ , IL-1 $\beta$ , and IL-6) and eosinophil chemotactic (CCL24 and CCL26) molecules (Fig. 4A, B). For instance, compared with control fibroblasts, TNF- $\alpha$  was significantly increased by the presence of IL-33-stimulated eosinophils (10-fold;  $P < 0.05$  [24 h]) (7-fold;  $P < 0.01$  [48 h]) (Fig. 4A). IL-1 $\beta$  was increased 3.4-fold ( $P < 0.05$  [24 h]) (Fig. 4A), whereas IL-6 was increased 2-fold ( $P < 0.05$  [24 h]) and 13.5-fold ( $P = 0.18$  [48 h]) (Fig. 4A).

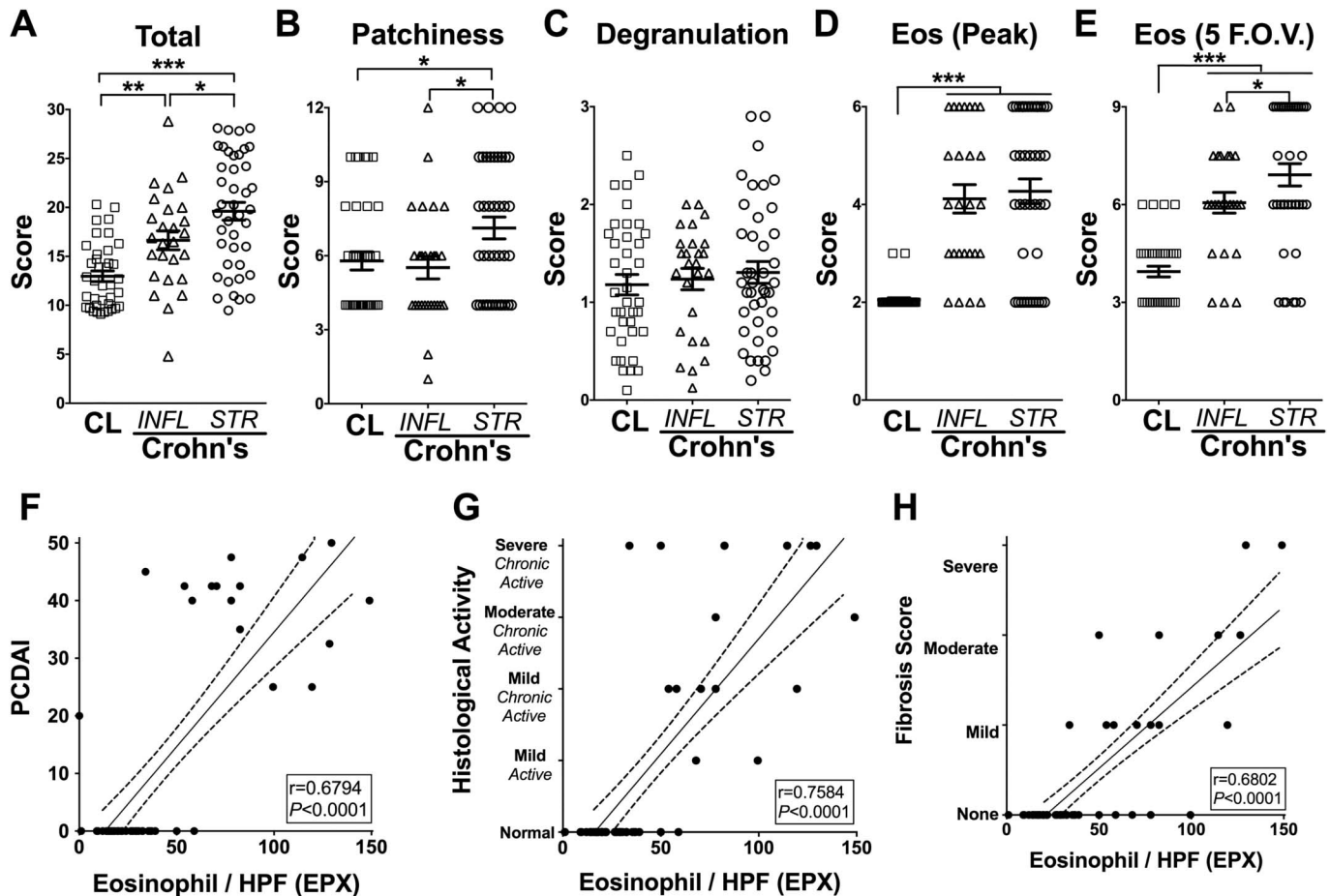


FIGURE 2. Distinguishing stricturing Crohn's ileitis using EPX immunohistochemistry-based scoring system. Eosinophil infiltration correlates with disease activity, chronicity, and fibrosis. EPX immunohistochemistry provides a quantitatively sensitive strategy to distinguish inflammatory from stricturing CD specimens. Examination of the scores for individual EPX parameters associated with all control (CL), inflammatory (INFL), or stricturing (STR) patients with CD found in Table 1 demonstrated differences between (A) their overall scores, in addition to individual parameters comprising the EPX algorithm: (B) patchiness, (C) degranulation, (D) peak eosinophils/HPF, and (E) average eosinophils across 5 random fields of view (F.O.V.). Statistical assessments (analysis of variance with Newman-Keuls) of the EPX staining scores (mean  $\pm$  SEM) demonstrated the utility of this algorithm to distinguish between stricturing and inflammatory CD mucosal specimens.  $*P \leq 0.05$ ,  $**P \leq 0.01$ ,  $***P \leq 0.001$ . Peak numbers of ileal eosinophils/HPF (EPX) were analyzed for relationships to subjects' (F) PCDAI, (G) histological activity and (H) fibrosis score measured in H&E-stained tissues for subjects defined in Table 1 that were not considered under treatment relevant to their CD. The Pearson's correlation coefficient (r) and its associated statistical significance are shown.

In addition, the increased production of the eosinophil-associated chemokines CCL24 (Eotaxin-2) and CCL26 (Eotaxin-3) also demonstrated the potential for further eosinophil recruitment by fibroblasts. Compared with control fibroblasts, CCL24 was significantly increased by the presence of IL-33-stimulated eosinophils (7-fold;  $P < 0.01$  [24 h]) (4.2-fold;  $P < 0.01$  [48 h]) (Fig. 4B). CCL26 was increased 1.7-fold ( $P < 0.05$  [24 h]) (Fig. 4B), and changes in CCL11 (Eotaxin-1) production were not found.

The expression of the cytokine receptor IL-13R $\alpha$ 2 was also significantly increased (Fig. 4C-iii). IL-13R $\alpha$ 2 has been described as a mediator of IL-13-induced intestinal fibrosis or as an IL-13 antagonist in other organs.<sup>18,19</sup> To investigate the role of increased fibroblast IL-13R $\alpha$ 2 expression after IL-33-stimulated eosinophil

coculture, we followed this coculture by removing the eosinophils and secreted mediators and subsequently stimulated these "primed" intestinal fibroblasts with IL-13 in fresh media. Fibroblasts first cultured in the presence of IL-33-stimulated eosinophils and subsequently stimulated with IL-13-induced significant production of COL1A2 when compared with fibroblasts first cultured in the presence of eosinophils alone with subsequent IL-13 stimulation (4.5-fold versus 3.3-fold;  $P < 0.05$ ) (Fig. 4D). A similar induction of fibronectin (1.7-fold versus 1.5-fold;  $P < 0.05$ ), and periostin (11.7-fold versus 6.5-fold;  $P < 0.05$ ) was also established (Fig. 4D). Here, we determined a clear 2-step method by which IL-33-stimulated eosinophils mediate the "priming" of intestinal fibroblasts for subsequent IL-13-induced profibrotic activity.

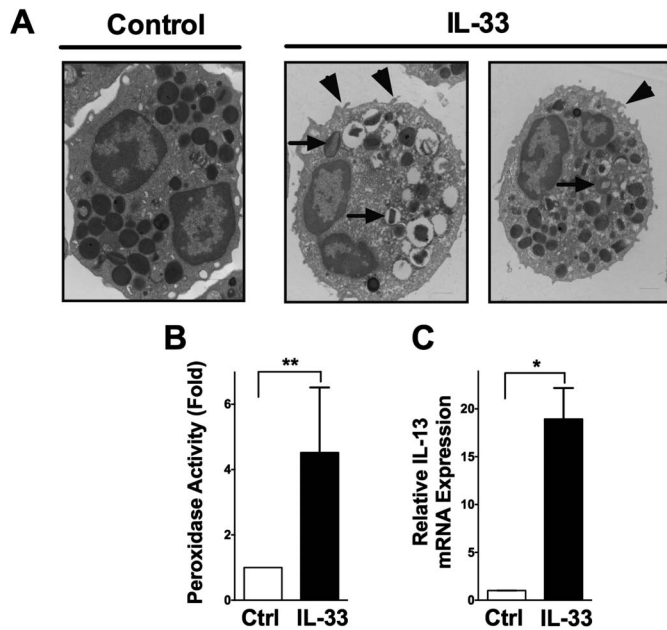


FIGURE 3. Circulating eosinophils are activated by IL-33. Circulating eosinophils were isolated and subjected to IL-33 stimulation (100 ng/mL) for 3 hours and then assessed for evidence of activation. A, Representative electron micrographs provide evidence of eosinophil activation (right) compared with untreated controls (left), including reversal of granule staining consistent with degranulation (arrows), and membrane ruffling (arrowheads). B, Biochemical measures of peroxidase activity in cell-free supernatants from control and IL-33-stimulated eosinophils (3 h, 100 ng/mL) were performed. C, Eosinophil IL-13 mRNA expression analysis was performed by real-time PCR on extracted RNA from control and IL-33-stimulated eosinophils (3 h, 100 ng/mL). Data are expressed as mean  $\pm$  SEM of 4 individual donors. Statistical significance was assessed using the nonparametric Mann-Whitney U test compared with untreated controls. \* $P \leq 0.05$ , \*\* $P \leq 0.01$ .

### IL-33 Is Increased in Pediatric Ileal CD and Associated with Eosinophilia and Histological Evidence of Disease Chronicity

Because IL-33 can stimulate the influx of eosinophils into inflamed tissues and elicit their activation, we next examined intestinal epithelial IL-33 in pediatric tissues affected by CD using immunohistochemistry (Fig. 5). IL-33 was most strongly detected in endothelial cell nuclei and in infiltrating lamina propria cells, epithelial cells, Paneth cell granules and could sometimes be detected as cell-free cytokine within extracellular spaces. Epithelial IL-33 was detected more frequently in epithelial cells of the crypts than villi and was located in both the cytoplasm and nucleus of these cells, consistent with previous reports examining Crohn's and ulcerative colitis specimens.<sup>20–22</sup> Epithelial IL-33 was significantly increased in untreated inflammatory ( $1.6 \pm 0.08$ ;  $P < 0.001$ ) and stricturing ( $1.3 \pm 0.06$ ;  $P < 0.001$ ) CD subjects' specimens compared with controls ( $0.45 \pm 0.05$ ) (Fig. 5A, B). Interestingly, CD-related treatments had no effect on epithelial

IL-33 levels in either group. Correlation analysis determined a significant relationship between the increasing presence of epithelial IL-33 and PCDAI ( $r = 0.75$ ,  $P < 0.001$ ), histologic activity ( $r = 0.71$ ,  $P < 0.001$ ), and numbers of eosinophils ( $r = 0.6$ ,  $P < 0.001$ ) (Fig. 5C–E). A significant correlation was also detected between epithelial IL-33 and fibrosis ( $r = 0.5969$ ,  $P < 0.001$ ) (Fig. 5F). A modest but statistically significant relationship existed between cell-free/extracellular IL-33 and eosinophil degranulation ( $r = 0.2760$ ,  $P < 0.05$ ) in addition to fibrosis ( $r = 0.4529$ ,  $P = 0.001$ ).

## DISCUSSION

Fibrostenotic ileal CD represents a poorly understood pediatric patient phenotype that frequently requires surgical resection. Identification of predisposing factors, novel biomarkers, and therapeutic targets associated with this group of patients could provide earlier diagnosis and medical intervention. Because of an increasing body of work that supports a role for eosinophils in fibrotic diseases outside of the gastrointestinal tract, we wondered whether accumulation and activation of this cell was associated with pediatric ileal stricturing CD. To address this, we used immunohistochemical staining for EPX to fully capture a number of key features related to eosinophil infiltration and translated our findings to assess the role of IL-33, a key fibrogenic molecule, in activating eosinophils to promote a stenotic phenotype. Histological assessments with EPX revealed that the degree and localization pattern of eosinophilic inflammation distinguished stricturing pediatric CD compared with inflammatory pediatric CD. In addition, our data elucidate the lack of sensitivity, specifically in fibrostenotic pediatric CD, of H&E staining for the study of eosinophils' role(s) in intestinal inflammation. Activation of eosinophils by IL-33 led not only to degranulation but also to production of IL-13 and fibroblast production of a number of downstream molecules associated with fibrosis. Together, these findings provide support for a possible pathogenetic role of eosinophils in the remodeling events that lead to pathological fibrostenosis in pediatric CD.

Clinical studies examining eosinophils' role in IBD, especially those focusing on complicated pediatric CD, are limited due to a number of factors including small numbers of patients, inadequate methodologies to detect eosinophils, variability of eosinophil number along the gastrointestinal tract, and lack of information regarding treatments taken by study subjects before specimen procurement. In fact, few studies have defined a "normal" number of eosinophils along the gastrointestinal tract of children, thus making comparisons between control and diseased tissues difficult. Regarding our overall hypothesis, we carefully defined this unique and large group of ileal stenotic pediatric patients and compared them with relevant pediatric noninflamed controls. To address a central issue of capturing the full content of eosinophilic inflammation, we used an eosinophil granule-specific immunohistochemical stain to develop a scoring index rather than just using the single metric of eosinophil number. Careful and

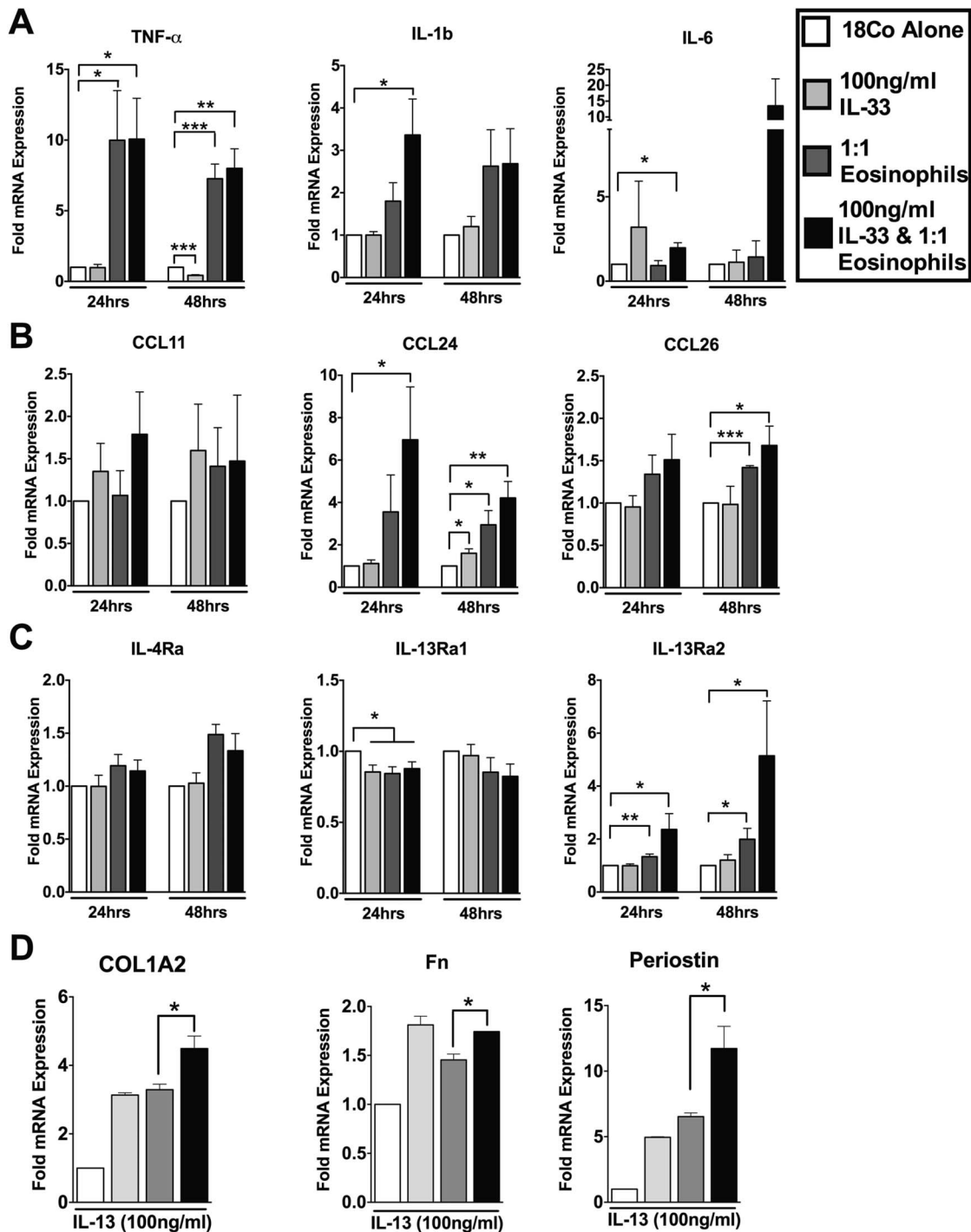


FIGURE 4. IL-33-activated eosinophils induce proinflammatory intestinal fibroblast activation and perpetuation of eosinophil recruitment *in vitro*. Confluent 18Co intestinal fibroblasts cells were cocultured with IL-33 (100 ng/mL) and eosinophils. As controls 18Co cells treated with IL-33 alone (100 ng/mL), 18Co cells cocultured with eosinophils in the absence of IL-33 or 18Co cells alone were used. A, Proinflammatory cytokine, (B) eosinophilic chemokine, and (C) cytokine receptor mRNA analysis of 18Co fibroblasts was performed by real-time PCR on extracted RNA after 24 and 48 hours of coculture. In a second series of experiments, cells were treated in the 4 groups described above. After 48 hours of coculture, 18Co cells were washed and IL-13 (100 ng/mL) was placed into each of the wells. D, Fibrosis-associated molecule mRNA analysis of IL-13-stimulated 18Co fibroblasts was performed by real-time PCR on extracted RNA after an additional 72 hours of culture. Data are expressed as mean  $\pm$  SEM of 2 to 6 individual donors. Statistical significance was assessed using 1-way analysis of variance with Newman-Keuls multiple comparisons test. \* $P \leq 0.05$ , \*\* $P \leq 0.01$ , \*\*\* $P \leq 0.001$ .



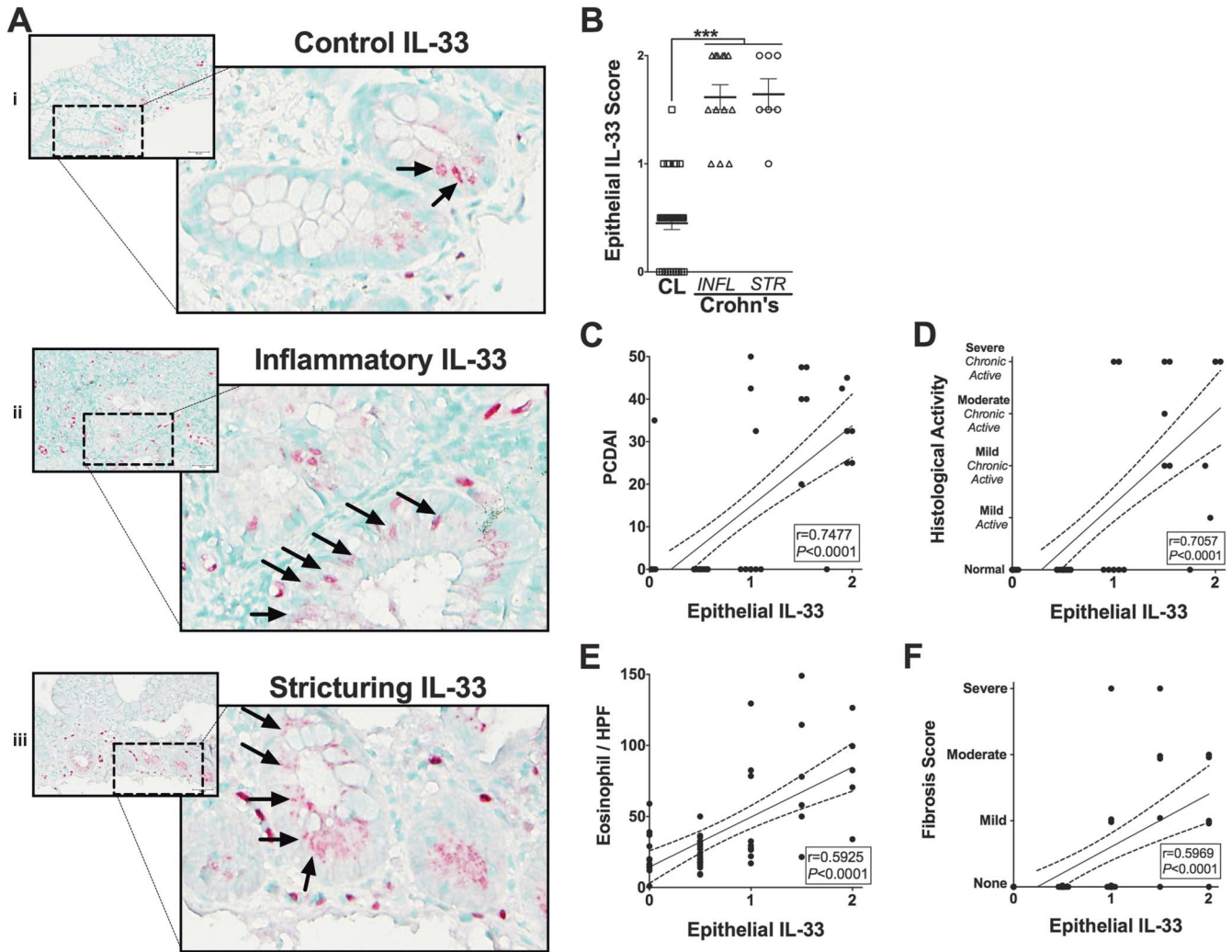


FIGURE 5. Epithelial IL-33 expression is associated with disease progression and eosinophilia in complicated CD. Representative photomicrographs of IL-33 immunohistochemically stained ileal tissues from (A-i) control (CL) subjects or from patients with (A-ii) inflammatory (INFL) or (A-iii) stricturing (STR) CD. Arrows indicate epithelial-IL-33. B, A score was generated to quantify the absence (0), presence (1), or increased presence (2) of epithelial IL-33 staining. Epithelial IL-33 scores were analyzed for relationships to subjects' (C) PCDAI, (D) histological activity, and (E) peak eosinophils/HPF (EPX), and (F) fibrosis score measured in H&E-stained tissues. All analyses were performed on subjects defined in Table 1, which were not considered under treatment relevant to their CD. Statistical significance was assessed for epithelial IL-33 scores by using 1-way analysis of variance with Newman–Keuls multiple comparisons test.  $***P \leq 0.001$ . For all other analysis, the Pearson's correlation coefficient ( $r$ ) and its associated statistical significance are shown.

through patient selection and tissue analysis created the unique set of findings presented here.

A number of previous studies have documented the profound accumulation of eosinophils in mucosal tissues from patients with pathologically and phenotypically undefined IBD, but their role within this microenvironment remains uncertain. An urgent need exists to begin targeting specific mechanisms including eosinophils' role in specific aspects of mucosal dysfunction. In this regard, eosinophils have been shown to participate directly as an effector cell in barrier dysfunction, goblet cell hyperplasia, and muscle contraction.<sup>7,23,24</sup> In the intestine, eosinophils *in vitro* have been directly implicated in the activation of

intestinal fibroblasts, resulting in fibroblast proliferation, the production of fibronectin, collagen, collagen gel contraction, IL-6 and IL-8 secretion.<sup>4–6</sup> In addition, eosinophils may communicate with other resident cells to initiate or perpetuate an inflammatory response. In support of our results, recent *in vitro* studies examined the impact of IL-33 on not only fibrosis but also eosinophil activation. For instance, IL-33–stimulated eosinophils adhere to matrix and connective tissue proteins and secrete significant quantities of IL-8 compared with control eosinophils.<sup>25–29</sup> Exposure of mouse bone marrow–derived eosinophils to IL-33 results in the production of IL-13.<sup>30</sup> Because human eosinophils are one of the key sources of IL-13, we sought to determine whether IL-33 could

directly stimulate IL-13 production and for the first time show this in human eosinophils.<sup>30–38</sup> In addition, coculture of “primed” fibroblasts with IL-33-activated eosinophils led to increased IL-13R $\alpha$ 2 expression and downstream to IL-13-induced profibrotic molecule expression. These findings bear relevance since Fichtner-Feigl et al previously defined the crucial role of IL-13 signaling through IL-13R $\alpha$ 2 in intestinal fibrosis using chronic mouse models.<sup>18,39–41</sup>

To date, eosinophil production of IL-13 has not been studied in the context of eosinophil–fibroblast interactions and the subsequent activation and perpetuation of fibrogenic processes in the intestines. Here, we show for the first time in a reductionist setting that eosinophil–fibroblast or IL-33–eosinophil–fibroblast cocultures lead to the induction of IL-13R $\alpha$ 2. Subsequent exposure of these intestinal fibroblasts to IL-13 leads to the production of fibrogenic molecules collagen 1a2, fibronectin, and periostin. Thus, eosinophils may contribute in a 2-step manner towards both perpetuation of inflammation and the potentiation of profibrotic activation of intestinal fibroblasts *in vitro*.

Fibrosis is considered a sequela to chronic inflammation, thus cytokines are an important factor in this process. IL-33 is produced by a wide range of cells in IBD including colonocytes<sup>20,22</sup> and colitis-associated myofibroblasts.<sup>42,43</sup> Previous studies have defined that IL-33 is increased in active IBD samples compared with uninvolved or control specimens.<sup>20–22,42–45</sup> Not all studies refer to the site of specimen collection; however, there is enough evidence currently to state that IL-33 expression is increased in colonic IBD and seems most prominent in ulcerative colitis. Studies of CD and IL-33 have been limited in specimen number and mainly to colonic location. IL-33 has been implicated in the fibrotic process in other organs.<sup>17,46–50</sup> Thus, ours is the first significantly powered study of IL-33 comparing inflammatory and stricturing disease in pediatric Crohn’s ileitis specimens. We report here that epithelial IL-33 is increased in ileal localized pediatric Crohn’s IBD. This IL-33 is associated with increased PCDAI, histological activity, eosinophilic infiltration, and more severe fibrosis score.

The clinical relevance of these findings is based on 2 highly significant correlations. First, while our novel metrics of eosinophilic inflammation was able to distinguish inflammatory from structuring pediatric CD, peak eosinophil values were also highly correlative with PCDAI and histological features of chronicity and fibrosis. Second, epithelial IL-33 expression in ileal tissues was also highly correlative with eosinophilia, PCDAI, and histological evidence of chronicity.<sup>51,52</sup>

Our findings are consistent with a growing body of interest and that of our previous study that suggested the association between eosinophils and bowel wall thickening in pediatric patients with eosinophilic colitis and with esophageal remodeling in eosinophilic esophagitis.<sup>53,54</sup> Here, using a new and more potent double-antibody eosinophil-targeted treatment, we reinforce our previous findings demonstrating the positive impact of single-antibody eosinophil-targeted treatment on ileal inflammation and remodeling.<sup>7</sup>

The pathogenesis of CD-related strictures is not fully understood, but ileal disease and duration of disease are

considered risk factors. The cells most implicated in this process are those of mesenchymal origin including fibroblasts, smooth muscle cells, and recruited or transdifferentiated mesenchymal-like cells.<sup>55</sup> Once activated by profibrogenic mediators such as TGF- $\beta$  and IL-13, these cells proliferate and produce fibrotic molecules such as collagen, fibronectin, and periostin. The production of an excessive amount of these cells and molecules leads to tissue thickening and stiffness and eventually to stricture. Growing evidence supports a new paradigm whereby fibroblasts contribute to initiation and perpetuation of inflammatory processes independent of their structural and fibrogenic roles during chronic disease.<sup>56</sup> Another study of colonic myofibroblasts has shown that type-2 cytokines regulate the eosinophil–chemokine eotaxin-3 expression.<sup>57</sup> Here, we provide evidence for the first time that eosinophils and, in addition, IL-33-stimulated eosinophils induce intestinal fibroblast production of proinflammatory cytokines TNF- $\alpha$ , IL-1 $\beta$ , and IL-6 and eosinophilic–chemokines eotaxin-2 (CCL24) and eotaxin-3 (CCL26). Thus, IL-33–eosinophil–fibroblast interactions may act to perpetuate intestinal inflammation and eosinophilia by both cytokine and chemokine production.

Our findings are limited by the lack of longitudinal data from our specimens. Future studies should consider examining eosinophilia over the course of disease in paired samples before and after stricturing in addition to increased numbers of specimens with and without treatment. Due to the rare nature of these specimens, this should be a heavily powered long-term study. Similar to coculture experiments reported here, studies examining eosinophils’ role in esophageal and dermal fibroblast activation determined the necessity for contact between eosinophils and fibroblasts.<sup>29,31</sup> Future studies should examine the role of soluble mediators versus juxtacrine signaling between eosinophils and fibroblasts in mediating inflammatory and fibrogenic processes. Previous studies have associated epithelial IL-33 with inflammatory ulcerative colitis in adults. Here, we report associations between epithelial IL-33 and fibrostenotic pediatric Crohn’s ileitis. Future studies need to consider dissection of IL-33 in fibrotic clinical complications of chronic disease, including quantitative comparisons between these 2 anatomical sites. Clinical implications of our study now highlight the need to examine eosinophilia when histologically assessing specimens from patients with CD. Our data demonstrate that altered mucosal eosinophil patterns determined by our EPX scoring system can differentiate inflammatory versus stricturing ileal mucosal specimens, and that this is independent of disease duration.

Here, we have added to previous studies in mouse models indicating that eosinophils play a significant role in ileal remodeling and fibrosis in specimens from pediatric patients with CD. These studies established that fibrosis occurring in pediatric ileal CD is associated with greater eosinophilic inflammation, epithelial IL-33 expression and mediated in part by IL-33, eosinophils, and IL-13 signaling in intestinal fibroblasts. Additional studies are planned to address a longitudinal examination of eosinophils in the progression toward fibrosis in pediatric and adult CD. Our data add to a growing body of literature dissecting the mechanisms of

fibrostenosis in CD, implicating eosinophils and eosinophil-derived mediators as viable targets in CD-related strictures.

## ACKNOWLEDGMENTS

The authors wish to thank the members of all the participating laboratories and the members of the Gastrointestinal Eosinophilic Diseases Program Children's Hospital Colorado for insightful discussions and critical comments. They also wish to acknowledge the invaluable assistance in animal husbandry and care at University of Colorado School of Medicine (Kristann Magee) and the administrative support provided by Joshua Rosenfeld, Linda Mardel, and Shirley ("Charlie") Kern. They gratefully thank Eric Wartchow for technical assistance on electron microscopy. They thank the physicians (Robert Kramer, Edward Hoffenberg, Edwin Liu, E. F. de Zoeten, David Brumbaugh, Christine Waasdorp, Shikha Sundaram, Cara Mack, Michael Narkewicz, Ronald Sokol, Jason Soden, and Deborah Neigut), and nurses (Tammy Armstrong, Sharon Mooney, and Jo Anne Newton), research assistants (Zachary Robinson and Joseph Ruybal), pathology staff (Sara Garza), research coordinators (Wendy Moore and Alyson Yeckes), and endoscopy technical staff (Bill Markovich) who contributed to this work by helping to provide and collect samples. We are grateful to our patients and families who were part of this study.

## REFERENCES

- Thia KT, Sandborn WJ, Harmsen WS, et al. Risk factors associated with progression to intestinal complications of Crohn's disease in a population-based cohort. *Gastroenterology*. 2010;139:1147–1155.
- Gupta N, Bostrom AG, Kirschner BS, et al. Incidence of stricturing and penetrating complications of Crohn's disease diagnosed in pediatric patients. *Inflamm Bowel Dis*. 2010;16:638–644.
- Henderson P, van Limbergen JE, Wilson DC, et al. Genetics of childhood-onset inflammatory bowel disease. *Inflamm Bowel Dis*. 2011;17:346–361.
- Furuta GT, Ackerman SJ, Varga J, et al. Eosinophil granule-derived major basic protein induces IL-8 expression in human intestinal myofibroblasts. *Clin Exp Immunol*. 2000;122:35–40.
- Gomes I, Mathur SK, Espenshade BM, et al. Eosinophil-fibroblast interactions induce fibroblast IL-6 secretion and extracellular matrix gene expression: implications in fibrogenesis. *J Allergy Clin Immunol*. 2005;116:796–804.
- Xu X, Rivkind A, Pikarsky A, et al. Mast cells and eosinophils have a potential profibrogenic role in Crohn disease. *Scand J Gastroenterol*. 2004;39:440–447.
- Masterson JC, McNamee EN, Jedlicka P, et al. CCR3 Blockade Attenuates Eosinophilic Ileitis and Associated Remodeling. *Am J Pathol*. 2011;179:2302–2314.
- Takedatsu H, Mitsuyama K, Matsumoto S, et al. Interleukin-5 participates in the pathogenesis of ileitis in SAMPl/Yit mice. *Eur J Immunol*. 2004;34:1561–1569.
- Takeda T, Hosokawa M, Takeshita S, et al. A new murine model of accelerated senescence. *Mech Ageing Dev*. 1981;17:183–194.
- Justice JP, Borchers MT, Crosby JR, et al. Ablation of eosinophils leads to a reduction of allergen-induced pulmonary pathology. *Am J Physiol Lung Cell Mol Physiol*. 2003;284:L169–L178.
- Masterson JC, McNamee EN, Fillon SA, et al. Eosinophil-mediated signalling attenuates inflammatory responses in experimental colitis. *Gut*. 2014;64:1236–1247.
- McNamee EN, Wermers JD, Masterson JC, et al. Novel model of TH2-polarized chronic ileitis: the SAMPl mouse. *Inflamm Bowel Dis*. 2010;16:743–752.
- Hyams JS, Ferry GD, Mandel FS, et al. Development and validation of a pediatric Crohn's disease activity index. *J Pediatr Gastroenterol Nutr*. 1991;12:439–447.
- Protheroe C, Woodruff SA, de Petris G, et al. A novel histologic scoring system to evaluate mucosal biopsies from patients with eosinophilic esophagitis. *Clin Gastroenterol Hepatol*. 2009;7:749–755.e711.
- Colgan SP, Dzus AL, Parkos CA. Epithelial exposure to hypoxia modulates neutrophil transepithelial migration. *J Exp Med*. 1996;184:1003–1015.
- Capocelli KE, Fernando SD, Menard-Katcher C, et al. Ultrastructural features of eosinophilic oesophagitis: impact of treatment on desmosomes. *J Clin Pathol*. 2015;68:51–56.
- Rankin AL, Mumm JB, Murphy E, et al. IL-33 induces IL-13-dependent cutaneous fibrosis. *J Immunol*. 2010;184:1526–1535.
- Fichtner-Feigl S, Strober W, Kawakami K, et al. IL-13 signaling through the IL-13alpha2 receptor is involved in induction of TGF-beta1 production and fibrosis. *Nat Med*. 2006;12:99–106.
- Mentink-Kane MM, Wynn TA. Opposing roles for IL-13 and IL-13 receptor alpha 2 in health and disease. *Immunol Rev*. 2004;202:191–202.
- Beltran CJ, Nunez LE, Diaz-Jimenez D, et al. Characterization of the novel ST2/IL-33 system in patients with inflammatory bowel disease. *Inflamm Bowel Dis*. 2010;16:1097–1107.
- Pastorelli L, Garg RR, Hoang SB, et al. Epithelial-derived IL-33 and its receptor ST2 are dysregulated in ulcerative colitis and in experimental Th1/Th2 driven enteritis. *Proc Natl Acad Sci U S A*. 2010;107:8017–8022.
- Seidelin JB, Bjerrum JT, Coskun M, et al. IL-33 is upregulated in colonoocytes of ulcerative colitis. *Immunol Lett*. 2010;128:80–85.
- Furuta GT, Nieuwenhuis EE, Karhausen J, et al. Eosinophils alter colonic epithelial barrier function: role for major basic protein. *Am J Physiol Gastrointest Liver Physiol*. 2005;289:G890–G897.
- Jacoby DB, Gleich GJ, Fryer AD. Human eosinophil major basic protein is an endogenous allosteric antagonist at the inhibitory muscarinic M2 receptor. *J Clin Invest*. 1993;91:1314–1318.
- Cherry WB, Yoon J, Bartemes KR, et al. A novel IL-1 family cytokine, IL-33, potently activates human eosinophils. *J Allergy Clin Immunol*. 2008;121:1484–1490.
- Chow JY, Wong CK, Cheung PF, et al. Intracellular signaling mechanisms regulating the activation of human eosinophils by the novel Th2 cytokine IL-33: implications for allergic inflammation. *Cell Mol Immunol*. 2010;7:26–34.
- Pecaric-Petkovic T, Didichenko SA, Kaempfer S, et al. Human basophils and eosinophils are the direct target leukocytes of the novel IL-1 family member IL-33. *Blood*. 2009;113:1526–1534.
- Suzukawa M, Koketsu R, Iikura M, et al. Interleukin-33 enhances adhesion, CD11b expression and survival in human eosinophils. *Lab Invest*. 2008;88:1245–1253.
- Wong CK, Leung KM, Qiu HN, et al. Activation of eosinophils interacting with dermal fibroblasts by pruritogenic cytokine IL-31 and alarmin IL-33: implications in atopic dermatitis. *PLoS One*. 2012;7:e29815.
- Bouffi C, Rochman M, Zust CB, et al. IL-33 markedly activates murine eosinophils by an NF-kappaB-dependent mechanism differentially dependent upon an IL-4-driven autoinflammatory loop. *J Immunol*. 2013;191:4317–4325.
- Rieder F, Nonevski I, Ma J, et al. T-helper 2 cytokines, transforming growth factor beta1, and eosinophil products induce fibrogenesis and alter muscle motility in patients with eosinophilic esophagitis. *Gastroenterology*. 2014;146:1266–1277.e1261–1269.
- Schmid-Grendelmeier P, Altnauer F, Fischer B, et al. Eosinophils express functional IL-13 in eosinophilic inflammatory diseases. *J Immunol*. 2002;169:1021–1027.
- Aceves SS, Chen D, Newbury RO, et al. Mast cells infiltrate the esophageal smooth muscle in patients with eosinophilic esophagitis, express TGF-beta1, and increase esophageal smooth muscle contraction. *J Allergy Clin Immunol*. 2010;126:1198–1204.e1194.
- Aceves SS, Newbury RO, Dohil R, et al. Esophageal remodeling in pediatric eosinophilic esophagitis. *J Allergy Clin Immunol*. 2007;119:206–212.
- Dyer KD, Percopo CM, Xie Z, et al. Mouse and human eosinophils degranulate in response to platelet-activating factor (PAF) and lysoPAF via a PAF-receptor-independent mechanism: evidence for a novel receptor. *J Immunol*. 2010;184:6327–6334.

36. Spencer LA, Szela CT, Perez SA, et al. Human eosinophils constitutively express multiple Th1, Th2, and immunoregulatory cytokines that are secreted rapidly and differentially. *J Leukoc Biol.* 2009;85:117–123.
37. Stolarski B, Kurowska-Stolarska M, Kewin P, et al. IL-33 exacerbates eosinophil-mediated airway inflammation. *J Immunol.* 2010;185:3472–3480.
38. Woerly G, Lacy P, Younes AB, et al. Human eosinophils express and release IL-13 following CD28-dependent activation. *J Leukoc Biol.* 2002;72:769–779.
39. Fichtner-Feigl S, Fuss IJ, Young CA, et al. Induction of IL-13 triggers TGF-beta1-dependent tissue fibrosis in chronic 2,4,6-trinitrobenzene sulfonic acid colitis. *J Immunol.* 2007;178:5859–5870.
40. Fichtner-Feigl S, Strober W, Geissler EK, et al. Cytokines mediating the induction of chronic colitis and colitis-associated fibrosis. *Mucosal Immunol.* 2008;1(suppl 1):S24–S27.
41. Fichtner-Feigl S, Young CA, Kitani A, et al. IL-13 signaling via IL-13R alpha2 induces major downstream fibrogenic factors mediating fibrosis in chronic TNBS colitis. *Gastroenterology.* 2008;135:2003–2013, 2013. e2001–2007.
42. Sponheim J, Pollheimer J, Olsen T, et al. Inflammatory bowel disease-associated interleukin-33 is preferentially expressed in ulceration-associated myofibroblasts. *Am J Pathol.* 2010;177:2804–2815.
43. Kobori A, Yagi Y, Imaeda H, et al. Interleukin-33 expression is specifically enhanced in inflamed mucosa of ulcerative colitis. *J Gastroenterol.* 2010;45:999–1007.
44. Sedhom MA, Pichery M, Murdoch JR, et al. Neutralisation of the interleukin-33/ST2 pathway ameliorates experimental colitis through enhancement of mucosal healing in mice. *Gut.* 2013;62:1714–1723.
45. Wakahara K, Baba N, Van VQ, et al. Human basophils interact with memory T cells to augment Th17 responses. *Blood.* 2012;120:4761–4771.
46. Li D, Guabiraba R, Besnard AG, et al. IL-33 promotes ST2-dependent lung fibrosis by the induction of alternatively activated macrophages and innate lymphoid cells in mice. *J Allergy Clin Immunol.* 2014;134:1422–1432.e1411.
47. Luzina IG, Kopach P, Lockatell V, et al. Interleukin-33 potentiates bleomycin-induced lung injury. *Am J Respir Cell Mol Biol.* 2013;49:999–1008.
48. Sanchez-Mas J, Lax A, Asensio-Lopez Mdel C, et al. Modulation of IL-33/ST2 system in postinfarction heart failure: correlation with cardiac remodelling markers. *Eur J Clin Invest.* 2014;44:643–651.
49. Marvie P, Lisbonne M, L'Helgoualc'h A, et al. Interleukin-33 overexpression is associated with liver fibrosis in mice and humans. *J Cell Mol Med.* 2010;14:1726–1739.
50. McHedlidze T, Waldner M, Zopf S, et al. Interleukin-33-dependent innate lymphoid cells mediate hepatic fibrosis. *Immunity.* 2013;39:357–371.
51. Bailey JR, Bland PW, Tarlton JF, et al. IL-13 promotes collagen accumulation in Crohn's disease fibrosis by down-regulation of fibroblast MMP synthesis: a role for innate lymphoid cells? *PLoS One.* 2012;7:e52332.
52. Scharl M, Frei S, Pesch T, et al. Interleukin-13 and transforming growth factor  $\beta$  synergise in the pathogenesis of human intestinal fistulae. *Gut.* 2013;62:63–72.
53. Brandon JL, Schroeder S, Furuta GT, et al. CT imaging features of eosinophilic colitis in children. *Pediatr Radiol.* 2013;43:697–702.
54. Kagalwalla AF, Akhtar N, Woodruff SA, et al. Eosinophilic esophagitis: epithelial mesenchymal transition contributes to esophageal remodeling and reverses with treatment. *J Allergy Clin Immunol.* 2012;129:1387–1396.e1387.
55. Rieder F, Fiocchi C. Intestinal fibrosis in inflammatory bowel disease: progress in basic and clinical science. *Curr Opin Gastroenterol.* 2008;24:462–468.
56. Li M, Riddle SR, Frid MG, et al. Emergence of fibroblasts with a proinflammatory epigenetically altered phenotype in severe hypoxic pulmonary hypertension. *J Immunol.* 2011;187:2711–2722.
57. Takahashi K, Imaeda H, Fujimoto T, et al. Regulation of eotaxin-3/CC chemokine ligand 26 expression by T helper type 2 cytokines in human colonic myofibroblasts. *Clin Exp Immunol.* 2013;173:323–331.