

# Isolation and identification of *Madurella mycetomatis* from two cases of black grain mycetoma in Libya

## Fallbericht. Isolierung und Identifizierung von *Madurella mycetomatis* in zwei Fällen von Eumyzetom in Libyen

M. S. Ellabib,<sup>1,2</sup> A. Refaai,<sup>1,2</sup> Z. Khalifa<sup>2</sup> and K. Kavanagh<sup>3</sup>

<sup>1</sup>Department of Medical Microbiology, Medical College, Al-Fateh University, Tripoli, Libya and <sup>2</sup>Mycology Section, Central Laboratory, Tripoli, Libya and <sup>3</sup>Department of Biology, National University of Ireland, Maynooth, Co Kildare, Ireland

### Summary

Two cases of mycetoma of the foot caused by *Madurella mycetomatis* are reported in which identification of the etiologic agents was confirmed by culture. A Libyan male aged 40 years and a Chadian female aged 30 years, exhibited eumycetoma of the foot 1 and 2 years, respectively, after a local injury. The diagnoses were based on the clinical presentation and confirmed by mycologic analysis of the grains and culture isolation of the etiologic agent. Prior to this report *M. mycetomatis* has not been recorded in Libya as a cause of eumycetoma.

### Zusammenfassung

Es werden zwei Fälle von Myzetom am Fuß vorgestellt. Bei einem 40-jähriger Mann aus Libyen entwickelte sich das Myzetom am rechten Fuß ein Jahr nach einer Verletzung. Eine 30 Jahre alte Frau aus Tschad stellte sich mit einem zwei Jahre alten Myzetom unklarer Genese am rechten Fuß vor. Als Erreger konnte in beiden Fällen *Madurella mycetomatis* isoliert werden. Es ist dies der erste Bericht über *M. mycetomatis*-bedingte Eumyzetome in Libyen.

**Key words:** *Madurella mycetomatis*, mycetoma, Libya.

**Schlüsselwörter:** *Madurella mycetomatis*, Myzetom, Libyen.

### Introduction

Mycetoma is a chronic granulomatous and progressive inflammatory disease that usually involves the subcutaneous tissue after a traumatic inoculation of the causative organism. The feet are most frequently affected with the hands, back, neck, and also the back of the head being infected. Typically, there is localized destruction of the skin, subcutaneous tissue and bones of the hands or feet.<sup>1</sup> The condition may be caused by true fungi or by

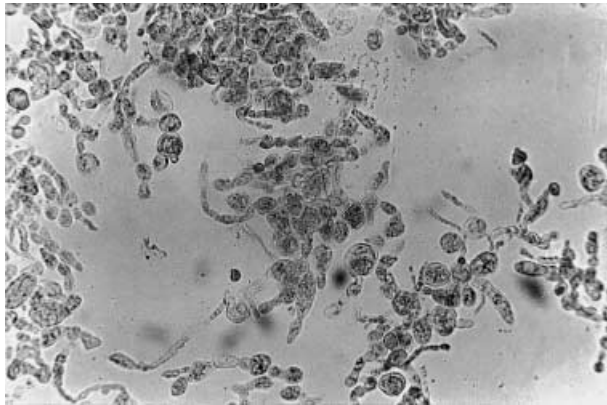
higher bacteria and therefore it is classified as eumycetoma or actinomycetoma, respectively.<sup>2</sup> In Africa, mycetoma is most frequently observed in tropical and subtropical regions such as Sudan, Senegal, Chad and other sub-Saharan countries.<sup>3</sup> However, eumycetoma has not been reported in Libya previously, because of the fact that most observed cases are hospital-based descriptions of advanced disease, and lack definitive diagnosis of the causative agent(s). In this report we present the first identification of the causative agent of eumycetoma from two cases submitted for examination to the mycology section of Tripoli Medical Centre.

### Case reports

Patient 1 was a 40-year-old male from the southern city of Sabha in Libya who had sustained a trauma of the

Correspondence: Dr Kevin Kavanagh, Medical Mycology Unit, Department of Biology, NUI Maynooth, Co. Kildare, Ireland.  
Tel.: 353-1-708 3859. Fax: 353-1-708 3845.  
E-mail: kevin.kavanagh@may.ie

Accepted for publication 12 May 2003

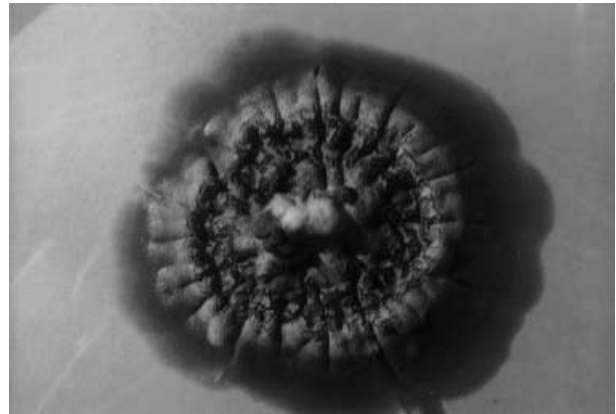


**Figure 1** Hyphae of *Madurella mycetomatis*. Hyphae were prepared in KOH and examined microscopically. Original magnification 400 $\times$ .

right foot using an axe while working on his farm, 1 year prior to examination. Patient 2 was a 30-year-old female from Chad who exhibited a mycetoma of right foot with unknown origin, which began developing 2 years prior to examination.

During their most recent hospital admission, the right foot of both the patients was swollen and the skin over the foot was darkly pigmented with more than one discharging sinus-tract containing black granules. Tissue biopsies and sinus discharge contained many hard black granules. Samples were sent to the mycology laboratory in sterile saline for microscopic examination and culture isolation of the causative agent. The granules were collected and washed in sterile saline. A few granules were crushed between two slides and examined in KOH mounts, which showed brown, septate hyphae that terminated in enlarged hyphal cells at the periphery of the granules. The cell wall pigment was minimal, but the hyphal cell contained brown particles (Fig. 1).

Several crushed and washed granules were cultured on plates of Sabouraud glucose agar containing chloramphenicol and gentamicin, and incubated at room temperature (approximately 25 °C) and 37 °C. Fungal growth was apparent on plates incubated at 37 °C after 2 weeks. Colonies that originated from the material obtained from both patients were slow growing and white at first, changing from olivaceous to yellow and brown after 1 month, dome-shaped, velvety with raised centre, folded with brown pigment and diffused into the medium (Figure 2). Plates, which were incubated at 30 °C failed to show any growth even after 1 month. Growth at 37 °C and microscopic examination of granules as well as colony morphology were used as



**Figure 2** Colony of *Madurella mycetomatis* grown on Sabouraud glucose agar at 37 °C for 4 weeks. Colony diameter is 3 cm.

diagnostic criteria to distinguish *Madurella mycetomatis* from *M. grisea*<sup>4</sup> which grows better at 30 °C. Wet mount microscopic examination of culture growth in lactophenol cotton blue showed septate hyphae, irregular in width with intercalary and terminal chlamydospores, which are typical characteristics of *M. mycetomatis*.

## Discussion

Eumycetoma has previously been reported in Sudan, Mali, Chad, and Niger.<sup>3, 5-7</sup> Although Libya is situated in the African zone, which is endemic for mycetoma and this condition has been recorded in Egypt, Tunisia, and Algeria,<sup>8-10</sup> which are geographically adjacent to Libya, the condition or isolation of etiologic agents has not been recorded in Libya to date. Eumycetoma may be prevalent in Libya or sporadic cases may occur. The lack of reported cases of eumycetoma in Libya in the medical literature may be due to the fact that diagnosis of most cases is based on clinical presentation without mycologic study for isolation and identification of the etiologic agent. However, in this study we present the first report of the isolation of *M. mycetomatis* from two cases in Libya.

Patient 2 may have contracted the disease while residing in Chad. However, patient 1 contracted the disease while living in Sabah (Libya), which strongly supports the view that *M. mycetomatis* may be as prevalent in Libya as in other countries along the endemic zone of mycetoma which includes Chad, Mali, Niger, and Sudan. The data presented here are the first reports of *M. mycetomatis* as the causative agent of eumycetoma in Libya and indicate that this disease

occurs in Libya, possibly at the same frequency as in adjacent countries.

### Acknowledgements

The authors are grateful to Mr Michael Weedle for his assistance in the preparation of the manuscript.

### References

- 1 Richardson M, Johnson E. *Fungal Infect*. London: Blackwell Science Ltd, 2000.
- 2 Magana M. Mycetoma. *Int J Dermatol* 1984; **23**: 1–236.
- 3 Develoux M, Ndiaye B, Dieng MT. Mycetoma in Africa. *Santé* 1995; **5**: 211–7.
- 4 Midgley G, Clayton Y, Hay RJ. *Diagnosis in color: medical mycology*. Mosby-Wolfe's: London, UK, 1997.
- 5 Mahgoub ES. Mycoses of the Sudan. *Trans R Soc Trop Med Hyg* 1977; **71**: 184–8.
- 6 Mahe M, Develoux M, Lienhardt C, Keita S, Bobin P. Mycetoma in Mali: causative agents and geographic distribution. *Am J Trop Med Hyg* 1995; **54**: 77–9.
- 7 Develoux M, Audoin J, Treguer J, Vetter JM, Warter A, Cenac A. Mycetoma in the Republic of Niger: clinical features and epidemiology. *Am J Trop Med Hyg* 1988; **38**: 386–90.
- 8 Abdei-Aal H, Karim AZ, Moawad MK, Kalifa TM. *Madurella mycetomi* as a cause of maduromycosis in Egypt. Clinical and mycopathological studies of two cases. *Dermatol Monatsschr* 1974; **160**: 670–4.
- 9 Daghfous M, Mokhtar I, Fazaa B, Kamoun MR. Anatomoclinical study of mycetomas. *Tunis Med* 1993; **71**: 529–34.
- 10 Destombes P, Rannou M, Nell R. Mycetoma due to *Streptomyces somaliensis* seen in Algeria in the South area of the Atlas mountains. *Bull Soc Pathol Exot Filiales* 1965; **58**: 1017–20.