

SELECTED SUMMARIES

Expert Summaries of Print and Digital Media

Marcia Cruz-Correa, Section Editor
David Schwartz, Section Editor

Joseph Anderson, White River Junction, VT
Johanna L. Chan, Houston, TX
Matthew A. Ciorba, St. Louis, MO
Massimo Colombo, Milan, Italy
Gregory A. Cote, Charleston, SC
Evan S. Dellon, Chapel Hill, NC
Alex Ford, Leeds, United Kingdom
Lauren B. Gerson, San Francisco, CA
David S. Goldberg, Philadelphia, PA
Samir Gupta, San Diego, CA

STAFF OF CONTRIBUTORS

Reena Khanna, London, Ontario, Canada
W. Ray Kim, Rochester, MN
Paul Y. Kwo, Stanford, CA
Uma Mahadevan, San Francisco, CA
Baha Moshiree, Miami, FL
Swati G. Patel, Aurora, CO
Laurent Peyrin-Biroulet, Vandoeuvre-lès-Nancy, France
Jesus Rivera-Nieves, San Diego, CA

Sameer Saini, Ann Arbor, MI
Ekihiro Seki, Los Angeles, CA
Amit Singal, Dallas, TX
Ryan W. Stidham, Ann Arbor, MI
Akbar Waljee, Ann Arbor, MI
Sachin Wani, Aurora, CO
Alastair J. M. Watson, Norwich, United Kingdom
Yana Zavros, Cincinnati, OH

Defective Lymphatics in Crohn's Disease: Tertiary Lymphoid Follicles Plug the Gap

Randolph GJ Bala S, Rahier JF, et al. Lymphoid aggregates remodel lymphatic collecting vessels that serve mesenteric lymph nodes in Crohn disease. *Am J Pathol* 2016;186:3066-3077.

The gut-associated lymphoid tissues are the guardians of the enteric immune system and integrate dietary and microbial stimuli to maintain immunologic tolerance. However, during periods of persistent chronic inflammation, such as in Crohn's disease (CD), a dysfunctional lymphatic system is a pathologic hallmark. Indeed, the predominant histopathologic features of CD are lymphocytic lymphangitis, occluded lymphatic vessels, and inflammatory granulomas. These trademark features of chronic disease are found in or around ectopic tertiary lymphoid tissues (TLT) in the inflamed lamina propria (*Gut* 2008;57:1-4). In addition, the presence of TLT at the base of aphthous ulcers is the earliest endoscopically evident lesion in CD and their appearance heralds recurrent disease within the neo-terminal ileum after ilectomy (*Gut* 1984;25:665-672). To date, the function of intestinal TLT and their impact on the etiology and pathogenesis of CD remains enigmatic, with limited experimental evidence as to their role. How TLT integrate into the pathophysiology of CD remains a critical question, yet clinical investigation into their development and function remains limited.

Randolph et al aimed to assess the integrity of mesenteric lymphatic vasculature in CD. First, they confirmed the previous findings generated from immunopathologic studies of intestinal mucosa, indicating defective lymphatic function during active disease. To achieve this, patent blue dye was injected into the serosa of ileal loops before surgical resection, highlighting afferent lymphatic vessels draining the lamina propria. This technique nicely demonstrated a deviation of normal lymphatic vessels in active CD, compared with non-CD counterparts and indicated a remodeling of the vasculature in the mesentery. Next, they used a 3-dimensional system to image whole mount sections from a patient cohort undergoing ilectomy



for stricturing CD (to obtain cm³ tissue coverage). Surprisingly, this work revealed advanced remodeling of the lymphatic vascular tracks, with the presence of ectopic lymphoid follicles within the collecting vessel line. A border of adipocytes and no evident capsule, suggesting that these organized structures were not sentinel lymph nodes but TLT instead. The work by Randolph et al highlights that, although most studies have reported on lymphatic capillaries in the intestinal wall, where collecting vessels remove solutes and immune cells, the primary functional site of lymphatic dysfunction may be the larger vessels in the mesentery, which interface with sentinel lymph nodes.

Comment. Our current understanding of the pathophysiology of CD points toward a complex and heterogeneous disease with an array of genetic and immunologic defects. Yet, a consistent and primary pathologic hallmark is the development of ectopic TLT and defective lymphatic vasculature. However, our understanding of the potential clinical significance of targeting lymphatics as a therapeutic strategy in CD is limited, given the paucity of preclinical and clinical studies investigating the biology of lymphatics in the setting of inflammatory bowel disease.

A pressing need raised by Randolph et al is to generate imaging techniques to investigate lymphatic function and identify the presence of TLT within mesenteric lymphatics of patients with CD, aiding in the assessment of clinical course and treatment response. Although the appearance of mesenteric TLT is a pathologic hallmark of treatment-refractory fibrostenotic disease at ilectomy, it is not known how and when they appear during the earlier stages of CD, or whether they are responsive to therapeutic intervention. Equally important is to achieve an understanding of the regional differences within the intestine (ie, ileal versus colonic CD). Surprisingly, an exhaustive pathologic characterization of TLT within the mucosa and mesentery of patients with CD is still lacking, hampering our ability to assess if the colon or ileum are more permissive for lymphatic vessel dysfunction or TLT development. The heterogeneous disease phenotypes and clinical courses of inflammatory bowel disease will surely have varying effects on regional lymphatic vessels and on sentinel lymph node function. In preclinical mouse models,

isolated lymphoid follicles and TLTs within the mucosa develop in response to inflammation and microbial stimuli, dissipating with antiinflammatory interventions (Gut 2013;62:53-62; J Immunol 2007;178:5659-5667). Whether the mesenteric TLTs identified by Randolph et al are regulated by the same immune cues or if they can be modulated by therapeutics (eg, vedolizumab) is not known.

The anatomic location of mesenteric TLT may give clues as to their function. It is debatable whether mucosal TLT are generated de novo within the chronically inflamed intestine or whether they represent hyperplasia and maturation of preexisting isolated lymphoid follicles. However, in the setting of the observations made by Randolph et al, ectopic TLT within afferent mesenteric lymphatics may either highlight an attempt to restore lymph node function (by generating new follicles and germinal centers) or alternatively indicate sites of vessel damage where TLTs form locally to contain disseminating microbes.

An intriguing question remains as to the function of these ectopic follicles and whether they are contributing to either a protective or pathologic immune environment. Are TLT generating secretory immunoglobulin (Ig)A to “man the border” following epithelial barrier defects and infiltration of pathobiont bacteria (similar to isolated lymphoid follicles)? Because IgA is not protective against invasive bacteria, they may be generating antibacterial IgG in an attempt to neutralize inflammation driven by invasive species. This process has been previously observed in mouse models with mesenteric fat-associated lymphoid clusters (Nat Immunol 2015;16:819-828) and in the setting of experimental colitis on a background of failed antimicrobial immunity (*ROR γ t*^{-/-} mice; J Exp Med 2011;208:125-134). Although extensive immunophenotyping of TLT was limited in this report, dense clusters of B cells with defined germinal centers were not observed by Randolph et al and CD20 immunopositive B cells within TLT presented with a diffuse pattern. However, TLT follicles were evident with segregated T-cell and B-cell compartments and mature high endothelial venules (as evidenced by PNA⁺ vessels), indicating immune maturity.

This latest report by Randolph et al recognizes the limitations of current mouse models, further supporting the need for experimental models that recapitulate the histopathologic features of CD. However, it is worth noting that the authors may not be aware that the *TNF*^{ΔARE} model has transmural pathology restricted to the ileum, florid TLT in mucosa, and marked induction of mesenteric fat-associated lymphoid clusters (Gut 2013;62:53-62; Nat Immunol 2015;16:819-828). Whether TLT are present within lymphatic vessels of the mesentery and contribute to vessel occlusion and remodeling in this model is yet to be identified. Furthermore, the *SAMP1YitFc* and *SAMP1* mouse strains further develop ileal restricted TLT and the appearance of “creeping fat” around the mesenteric vessels (Inflamm Bowel Dis 2010;16:743-752). A global caveat to using mouse models is that the lymphatic pump does not function in a similar manner to higher vertebrates and cannulating mouse mesenteric lymphatic vessels might not be yet feasible technically (Ann N Y Acad Sci 2010;1207

Suppl 1:E69-74). Thus, functionally assessing lymph flow in relation to ileal inflammation and ectopic TLT may require development of new murine (eg, rat) or primate models of CD.

Is there a therapeutic window to repair damaged afferent lymphatics and restore mucosal integrity during CD? From a therapeutics perspective, recent elegant work has demonstrated the efficacy of de novo lymphangiogenesis as a viable intervention to ameliorate colonic inflammation (J Clin Invest 2014;124:3863-3878). Danese et al used an adenoviral system to overexpress vascular endothelial growth factor-C, driving functional lymphatic vessel generation in the intestine that attenuated pathology in both dextran sodium sulfate-induced and *IL-10*^{-/-} colitis in mice. However, in light of the observations made by Randolph et al in fibrostenotic stricturing CD, it remains to be seen whether de novo generated lymphatic vessels can really integrate with functional sentinel lymph nodes in the mesentery to restore immune tolerance. Recent work assessing the impact of infection with *Yersinia pseudotuberculosis* demonstrated that infection induced damage to afferent lymphatic vessels and resulted in mesenteric bacterial leak, which persisted long after the infection was cleared, in addition to developing fibrotic mesenteric lymph nodes and compromised regional immunity (Cell 2015;163:354-366). Thus, permeable lymphatic vessels, fibrotic lymph nodes, and chylomicron leak may represent a point of no return for tissue integrity and function in CD.

A concern for the therapeutic dissociation of mesenteric TLT with the intent of reversing the vascular remodeling process is a potentially detrimental effect on regional antimicrobial immunity. For example, lymphotoxin- β receptor signaling is a critical cytokine cue for the development and organization of secondary lymphoid tissues and a multitude of studies have used lymphotoxin- β receptor blockade to disaggregate mature TLTs in various preclinical models of infection and autoimmunity. However, limited studies have reported on the subsequent impact on posttreatment pathology. Although lymphotoxin- β receptor inhibition will dissociate TLT in virtually all preclinical models reported, it has dramatic effects on lymph node structure and function including disruption of germinal centers, high endothelial venule repression (Immunity 2005;23:539-550) and altered dendritic cell ratios (J Immunol 2008;180:238-248). Although these experiments serve as proof-of-principle studies, the site-directed delivery of therapeutics that target TLT structure and function in CD, with limited effects on antimicrobial immunity may prove challenging. The report by Randolph et al emphasizes the need to investigate in detail the molecular signatures and regional differences of TLT from patients with inflammatory bowel disease, in an effort to identify novel therapeutic targets. Building on this work and understanding how mesenteric TLT integrate into enteric immunity (by controlling lymphocyte, dendritic cell, and antigen trafficking patterns) is sure to advance our understanding of TLT function and their role in CD pathophysiology. Given the marked lymphatic dysfunction in CD,

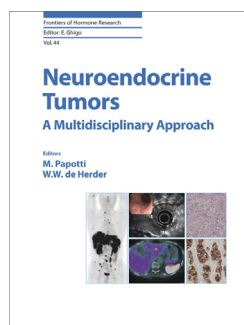
further efforts in this area will certainly expand our understanding of the pathogenesis of the disease.

EÓIN N. MCNAMEE

Mucosal Inflammation Program
School of Medicine
University of Colorado
Anschutz Medical Campus
Aurora, Colorado

JESUS RIVERA-NIEVES

Inflammatory Bowel Disease Center
Division of Gastroenterology
University of California San Diego and
San Diego VAMC
La Jolla, California



Neuroendocrine Tumors: A Multidisciplinary Approach.

M. Pappotti and W.W. de Herder, editors. 270 pp. \$254.00. Basel, Switzerland, Karger, 2015. ISBN: 978-3-318-02772-3. Web address for ordering: www.karger.com.

REVIEWER RATING

Coverage of relevant topics	★★★★
Improvement over previously available media	★★★★
Style of presentation and formatting	★★★★
Quality of figures	★★★★
Overall	★★★★

Stars:

★: poor; ★★: adequate; ★★★: fair; ★★★★: good; ★★★★★: excellent.

The incidence of neuroendocrine tumors (NETs) has increased multiple fold in the last 4 decades, providing more impetus for clinicians to understand the heterogeneity of NETs and to be able to recognize and treat these tumors effectively. For this reason, the editors of this book sought to provide a resource to those clinicians interested in this field. In this book, a diverse group of authors provides a multidisciplinary approach to the management of NETs, an understudied group of tumors. This book addresses the

more commonly encountered scenarios as well as unusual challenges that may arise in the clinical course. The book is comprehensive enough to serve as a reference book and readily provides answers to those with specific questions regarding NETs.

This book is a highly versatile book that would be useful for generalists as well as NET specialists. It includes a diverse array of topics including epidemiology, biomarkers, imaging, and pathology. Even more important, it provides a multidisciplinary approach to treatment, including endoscopic, surgical, medical, and peptide receptor radionuclide therapy. For those seeking answers to specific questions, the chapter titles clearly delineate the material covered in each chapter, ensuring that material is easy to find. The depth of coverage is complete and appropriate without overwhelming the reader. The diversity of the authors' specialties highlights the multidisciplinary approach often needed with these tumors, with perspectives written by gastroenterologists, endocrinologists, oncologists, and surgeons. The list of authors reads as a worldwide "who's who" of NET experts.

For gastroenterologists, the chapter on endoscopic approaches will prove particularly useful. Dermot O'Toole and Laurent Palazzo provide several figures demonstrating examples of gastroenteropancreatic NETs; these include endoscopic, endosonographic, and pathologic correlations. They also effectively elucidate some of the most frequently asked questions regarding gastric and duodenal NETs.

There are some limitations in this book. There is significant overlap in the surgical chapters. For example, surgical approaches for pancreatic NETs and metastatic disease are covered in both the pancreatic surgery and gastrointestinal surgery chapters. There is also some variability in the depth of coverage. The book does not include coverage of surgical approaches in lung or thymic NETs. Certain NETs, including ovarian and other rare tumors, are excluded. It would have been helpful to have staging and survival outcomes included. Although the staging classification is alluded to within the pathology chapter, more detail could have been provided in reference tables. Despite these limitations, the book remains a necessary resource in an understudied field.

Bottom Line: The book provides a practical review of the diagnosis, management, and surveillance of this diverse group of tumors. Although the focus of this book is clinical, it also provides a glimpse of current translational work in the field. Overall, the book is a much welcomed contribution to the existing NET literature.

MICHELLE KANG KIM, MD, PhD

Department of Medicine
Division of Gastroenterology
Mount Sinai School of Medicine
Mount Sinai Medical Center
New York, New York