



Published in final edited form as:

Curr Opin Gastroenterol. 2011 October ; 27(6): 515–522. doi:10.1097/MOG.0b013e32834b314c.

Update on clinical and immunological features of eosinophilic gastrointestinal diseases

Joanne C. Masterson^a, Glenn T. Furuta^a, and James J. Lee^b

^aDigestive Health Institute, Section of Pediatric Gastroenterology, Hepatology and Nutrition, Gastrointestinal Eosinophilic Diseases Program, Children's Hospital Colorado, National Jewish Health, Mucosal Inflammation Program, Department of Pediatrics, University of Colorado Denver School of Medicine, Aurora, Colorado

^bDepartment of Biochemistry, Mayo Clinic Scottsdale, Scottsdale, Arizona, USA

Abstract

Purpose of review—Eosinophilic gastrointestinal diseases (EGIDs) are an increasingly common heterogeneous group of intestinal diseases. The purpose of this review is to present the latest developments in the care of patients with EGIDs and to summarize a growing literature defining the clinical features and mechanistic elements of eosinophils and their complex relationships with the gastrointestinal tract.

Recent findings—Recent studies continue to define what constitutes 'normal' and 'abnormal' numbers of eosinophils in the different sections of the gastrointestinal tract. Symptom complexes of EGIDs appear to be related primarily to the mucosal, as opposed to the muscular or serosal, forms of EGIDs. Dissection of the mucosal microenvironment is uncovering a complex array of cells, other than eosinophils, that likely contribute to the inflammatory response associated with EGIDs. Mechanistic studies have identified genetic perturbations (eotaxin-3, thymic stromal lymphopoietin, IL-13, and filaggrin) that may also contribute to the development of the most often encountered and well studied EGID, eosinophilic esophagitis.

Summary—Clinicians should remain aware of EGIDs as a diagnostic possibility for patients with common gastrointestinal symptoms. Additional research is needed to determine mechanistic processes leading to dysfunction associated with eosinophilic gastrointestinal inflammation.

Keywords

eosinophilic esophagitis; eotaxin; filaggrin; mucosa; thymic stromal lymphopoietin

Introduction

Over the last decade, eosinophilic gastrointestinal diseases (EGIDs) have become increasingly recognized as a clinically relevant and mechanistically baffling group of conditions. Inherent in the diagnosis of these diseases is the finding of 'more than expected' eosinophils in the gastrointestinal tissues; what defines this number is an area of controversy and intrigue. Herein, we summarize clinical studies and identify controversies related to EGIDs.

Correspondence to Glenn T. Furuta, 13123 East 16th Avenue, B290, Aurora, CO 80045, USA, Tel: +1 727 777 7457; fax: +1 720 777 7277, glenn.furuta@childrenscolorado.org.

Conflicts of interest

G.T.F. has served as a consultant to Meritage Pharma, Nutricia, and Sunovion.

Gastrointestinal eosinophilia: what is in a number?

Except for the esophagus, all of the remaining gastrointestinal organs contain eosinophils. But, the ambiguity of what constitutes normal and abnormal numbers of eosinophils, contributes to significant confusion revolving around the care of patients with, and pathophysiological mechanisms defining, EGIDs. What are the diagnostic features of these diseases? What are the underlying homing and activation signals that drive the associated eosinophilic inflammation and the gastric, intestinal and/or bowel dysfunction in patients with EGIDs?

To date, the number of eosinophils per high power field (HPF) in a mucosal biopsy remains the gold standard defining histological diagnostic features of EGIDs [1]. Methodologies used to define these thresholds remain troublesome for several reasons including inconsistencies in definitions of what constitutes an eosinophil and the size of a HPF, variability in analysis between pathologists and gastrointestinal/allergy clinicians [2], inconsistencies in tissue orientation, limited amount of mucosal surface to assess, and most confusing, what defines normal and abnormal eosinophil numbers within various parts of the intestinal mucosae. Pathologists remain central to the diagnostic process [3–7].

If one considers EGIDs as a diagnosis, it is worth communicating with the pathologists to understand exactly how and why the specific inflammatory features are reported so that the results can be interpreted in the clinical context from which they were obtained. As these diseases become more common, patients and families are more informed and are beginning to understand how difficult these critical parameters are to define and, thus, may request more information about pathological reports.

Relatively few studies characterize what defines the normal number of eosinophils in the healthy gastrointestinal mucosae. This is a particularly difficult area of investigation because endoscopic sampling of the mucosa would not take place unless a clinical indication existed. One study began to address this issue by counting eosinophils in ‘whole tissue sections’ from the intestines of otherwise healthy infants and children who died acutely of causes other than gastrointestinal disease (trauma, etc.) [8]. Children ranged in age from 3 weeks to 17 years and a gradient of eosinophil numbers was identified ranging from a few in the stomach to a maximum of 50/HPF in the cecum. Another pediatric study showed virtually the same findings in ‘mucosal biopsy samples’ [9]. A third study examined histological features of the intestinal ‘mucosal biopsy samples’ from patients who exhibited a wide range of clinical features and found a similar gradient in the upper gastrointestinal tract [10]. Other studies determined the ‘normal’ number of eosinophils in the gastric mucosa (15 eos/HPF), colon (approximately Eosinophilic gastrointestinal diseases: clinical features of a heterogeneous group of conditions

Although a number of case reports have described the association of gastrointestinal symptoms with intestinal eosinophilia, the first and earliest comprehensive descriptions were provided by Kaijser [15] and Klein *et al.* [16] in publications separated by 33 years. In 1937, the single authored German publication by the surgeon Kaijser [15] described a series of patients with various abdominal symptoms and intestinal eosinophilia. In 1970, Klein *et al.* [16] proposed a novel classification system that separated patients with intestinal eosinophilia into anatomically distinct groupings, that is, mucosal, muscular, or serosal diseases, depending on where the predominant eosinophilia was located.

Subsequent to this, a number of investigators have further refined the description of EGIDs as organ-specific diseases, that is, eosinophilic esophagitis (EoE), eosinophilic gastritis, eosinophilic gastroenteritis, and eosinophilic colitis, depending on which part of the gastrointestinal tract is affected by eosinophilic inflammation [17]. Because eosinophils can

infiltrate the mucosa as a nonspecific feature of inflammation, other causes of eosinophilia need to be ruled out prior to assigning EGID as a diagnosis [18] (Table 1).

EoE is characterized by symptoms related to esophageal dysfunction; in the young child, symptoms include vomiting, abdominal pain, and feeding problems, whereas in older children and adults, dysphagia and food impactions [19] predominate [20,21]. Symptoms attributed to gastroesophageal reflux disease (GERD) that are recalcitrant to medical/surgical management of GERD can be, but are not always, presenting features of EoE [22]. Epidemiological data report an overall incidence of EoE as 1–5 in 10 000 with male sex predominance. Case series are increasing from previously underreported regions such as some parts of Europe, the Middle East, and Asia [4,23–25]. A family history of esophageal dilations is common. As the incidence grows and phenotypic descriptions expand, histological patterns are becoming more important. Eosinophil numbers remain the histological diagnostic feature but other components such as extracellular eosinophil granule deposition and other measures of inflammation (basal cell hyperplasia, rete peg elongation, dilated intercellular spaces, mastophilia, T cells, fibrosis, etc.) are also increased in the esophageal mucosa [26,27–30,31,32]. With respect to granule deposition, several studies have addressed this issue and suggest that the presence of extracellular granules occurs more often in the mucosa affected by EoE compared to GERD [33–36] (Fig. 1). A recently updated consensus report summarizes the most recent experiences and literature focusing on the clinical features and treatment of EoE [21]. See Table 2 for a summary of the changes from the original report [20].

Eosinophilic gastritis can present with abdominal pain, hematemesis, or vomiting alone, whereas eosinophilic gastroenteritis can manifest itself with these symptoms as well as anemia, diarrhea, or protein-losing enteropathy. Eosinophilic colitis typically can present with similar symptoms as above as well as bloody stools and can be mistaken for inflammatory bowel diseases. Two studies arising from tertiary care centers reported the world's largest clinical experiences and descriptions of the natural history of adults with EGIDs [37,38]. Talley et al., according to the Klein classification system, reported that over the course of the past 50 years, the pattern of EGIDs involvement has shifted to primarily a mucosal form. They note that 3 of the 4 million patients from their extensive database were found to have EGIDs and the incidence increased from one patient per year from 1950 to 1987 to three patients per year between 1987 and 2007. Follow-up revealed no significant complications.

Treatments for EGIDs remain limited to corticosteroids and diet restriction. EoE can effectively be treated with topical steroids [39,40], nutritional exclusions, and dilation [41–44]. Clinical experiences suggest that the more distal the eosinophilia from the esophagus, the less likely that a dietary allergen will be found to resolve symptoms and histopathological findings. In some circumstances, mast cell stabilizers and leukotriene antagonists may offer clinical benefit but no clinical trials have been performed. Novel biological agents such as anti-IL-5 antibody are on the horizon as potential new therapeutic agents for EoE and potentially other EGIDs.

Pathogenetic mechanisms: do not assume the obvious - could eosinophils have a homeostatic role in the gastrointestinal tract of healthy individuals?

The overwhelming focus of investigations linking pathology and symptoms in EGIDs often views the eosinophil as an interloper, a marauding proinflammatory leukocyte whose recruitment is a prelude to tissue destruction. However, this portrayal of the eosinophil belies the reality that, with the exception of the esophagus, the eosinophil is a prominent resident leukocyte of the gastrointestinal tract as discussed above and by others [45,46]. The presence of these resident eosinophils in otherwise healthy individuals leads to a paradox:

how is the presence of eosinophils necessary to maintain homeostasis at baseline and yet their presence is a hallmark and defining feature of EGIDs? We suggest that a better understanding of this paradox and, in turn, its resolution will provide a unique perspective to understand the role of eosinophils in EGIDs. There are three potential explanations for this paradox. First, resident eosinophils serve no role in the gastrointestinal tract in healthy individuals. As surprising as this statement may be, it had been one of the more common explanations offered for the presence of gastrointestinal eosinophils. In this hypothesis, the toxic character of eosinophils necessitated an extraordinary mechanism to remove these cells from the body. The gastrointestinal tract offered such a mechanism by acting as a sink for peripheral eosinophils as a means to remove these cells without collateral damage. Second, the activities of resident gastrointestinal eosinophils are inherently different from the pathological activities mediated by the recruited eosinophils accumulating as part of disease. Clearly, if one assumes that resident eosinophils have a functional role in healthy individuals and a pathological role in disease, the most parsimonious explanation for this duality is that the activities mediated by these two eosinophil populations are different. Indeed, the literature abounds with suggestions that eosinophils undergo one or more events leading to an inflammatory leukocyte that is unique relative to the 'resting' eosinophils found in peripheral circulation. These suggestions took many forms. On a morphological level, it was suggested that inflammatory eosinophils were hypodense relative to their 'resting' counterparts [47,48]. However, this vague more qualitative characterization gave way to specific molecular markers that correlated with the events described as eosinophil 'priming' or 'activation' [49–51]. As it related to the gastrointestinal tract, resting eosinophils may be sentinels whose presence was an early defensive shield to the possibility of microbial infection in a region that represented the largest environmental interface the body offers [52,53]. Thus, low numbers of eosinophils serve as sentinels that activate and multiply in number when confronting an infection. That is, gastrointestinal eosinophils in healthy individuals were 'resting' leukocytes that were triggered in response to pathogen. In this paradigm, EGIDs represent a form of immune dysfunction mimicking the events linked with parasite infection and in doing so, inadvertently unleash the nonspecific destructive capabilities of eosinophils; the ensuing tissue damage and local inflammatory events simply being unavoidable collateral damage. The third explanation for the presence of eosinophils in both health and disease suggests that resident eosinophils and those recruited during disease have exactly the same functions. The key for this hypothesis is that changing events in the gastrointestinal microenvironment elicit increases in the number, but not the activities, of eosinophils. The dynamic changes occurring in disease simply require more of the same eosinophil-mediated activities to maintain homeostasis. The fundamental issue in the case of the gastrointestinal tract is how eosinophils contribute to gut homeostasis and why are greater numbers of them required in disease states. Specifically, are these cells part of the immunomodulation of the mucosal microenvironment or are they agents of remodeling/repair linked to the continual and dynamic turnover of the gut epithelium? The point of interest here is that these proposed eosinophil activities are qualitatively the same in health and disease [54]. In this perspective, the immunoregulatory demands on the gut mucosal interface are enormous given the ubiquitous bacterial burden in this compartment. As such, the loss of epithelial barrier functions associated with many gastrointestinal diseases becomes a driver of eosinophil accumulation in these patients. Finally, epithelial cell turnover and stem cell activities require an ongoing commitment to remodeling/repair even in otherwise healthy individuals. Again, the damage linked with disease pathology would simply necessitate an increase in eosinophil numbers and, in turn, eosinophil-mediated remodeling/repair activities.

Eosinophilic esophagitis: increasing evidence for Th2 responses

Clinical practice is shedding light on the identification of different subtypes of patients with EoE, whereas translational and basic studies continue to provide more insights into the key elements defining the pathogenesis of this disease [55]. Together, these experiences and studies will provide direction toward novel therapeutic targets.

Genes

In addition to eotaxin-3, a number of other genes have now been associated with EoE, including transforming growth factor (TGF)-[beta]-1, filaggrin, and thymic stromal lymphopoietin (TSLP) [56–59]. TSLP is an epithelial derived IL-7-like cytokine that can activate a number of immune cells, in particular dendritic and mast cells. Filaggrin is a barrier gene that has been linked to barrier dysfunction in atopic dermatitis.

Epithelial immunomilieu: a diverse microenvironment is under definition

Eosinophils are the most readily recognized leukocyte associated with EoE, but they are not the only cells present in the affected esophageal mucosal surface. Studies measuring FoxP3 staining and human leukocyte antigen-DR expression in children and adult mucosae have been met with variable results [60–62]. A cell line of esophageal epithelia has been shown to possess the machinery to present antigen posing an interesting new paradigm for the pathogenesis of EoE [63].

Esophageal mucosae of adults and children with EoE were shown to have significantly increased mast cells [26,31,64]. Fibroblast growth factor expression in EoE tissues from children was associated with peripheral blood mononuclear cell expression of pro-apoptotic factors Fas and caspase-8 suggesting prolongation of eosinophil lifespan [65]. Although these studies continue to define the microenvironment associated with EoE, all patients may not have the same immunomilieu; future studies identifying the exact immunological features of specific clinical phenotypes may be difficult to measure but will be important to determine.

Mouse models and ex-vivo systems using human tissues support the concept that EoE is a Th2-driven disease. A recent comparative analysis of five EoE patients with five normal patients revealed more than four-fold upregulation of 19 cytokine genes (including eotaxin-3, IL-13, IL-5, IL-5r, CXCL1) and downregulation of two genes [breast and kidney-expressed chemokine (BRK) and IL-1F6] [66]. Of the upregulated genes, there was a significant correlation with disease activity. Other studies suggest EoE may be an IL-13 and/or IL-15 epithelial driven disease [67,68]. For instance, IL-15r null mice were protected from eosinophilia [67]. Ex-vivo analysis of esophageal epithelia revealed expression of both IL-15 and IL-15r, a finding that correlated with mucosal eosinophilia.

Chronic inflammation: mechanistic insights and functional impaction

The major clinical concern regarding chronic esophageal eosinophilia has been the impact of eosinophils and their products on remodeling, fibrosis, and stricture formation. This later potential impact has driven much of the vigor and attention to treatments. Clinical correlates identify increased fibrosis in the esophageal mucosa of children and adults with EoE, but criteria to measure this feature remain variable. To address this concern, a series of works identified a prominent role for TGF-[beta] in remodeling events in EoE and demonstrate a role for mast cells and TGF-[beta] in esophageal smooth muscle contraction [26]. Methodologies to measure esophageal function are lacking.

Recently, a study using the novel tool the endoflip, demonstrated reduced esophageal compliance in adults with EoE, a finding supportive of fibrosis or possibly increased

esophageal tone [69]. Together, these findings support the concept that eosinophilia can contribute to esophageal dysmotility, but who, how, and when these issues develop is unknown.

Eosinophilic gastritis and colitis: mechanistic elements

Although studies of the esophagus and other organ systems such as the lung have identified potential roles for eosinophils in stimulating tissue remodeling, inducing epithelial barrier dysfunction and smooth muscle contraction, few studies have addressed these issues in the rest of the gastrointestinal tract.

Previous studies focusing on the mechanisms of eosinophil recruitment identified the role of eotaxin-1 in the chemotaxis of eosinophils to the gastrointestinal mucosa. Utilizing bone marrow chimeras, a recent study demonstrated the impact of Ly6ChighCCR2+ monocyte/macrophage CCL11 on eosinophil recruitment in dextran sodium sulfate colitis [70]. A few studies have examined the impact of eosinophils on colonic function utilizing models of inflammatory bowel diseases.

For example, oxazolone-treated mice develop a Th2-type cytokine and colonic eosinophilia profile similar to ulcerative colitis [71]. Use of this mouse model in eosinophil granule protein null animals has demonstrated the pathological impact of major basic protein (MBP) and eosinophil peroxidase (EPO) in colitis.

Two studies showed that mice congenitally deficient in eosinophil development are protected from experimental colitis [71,72]. A spontaneous mouse model of ileitis, the SAMP1 mice, develops eosinophilia and ileal remodeling [73]. Mice treated with anti-CCR3 antibody responded with diminished eosinophilia, decreased goblet cell hyperplasia, and decreased smooth muscle mass [74].

Together, these studies support a role for eosinophils in lower gastrointestinal remodeling and dysfunction

Because of the potential role of allergic T-cell responses, IgE-mediated reactions have been considered as one of the mechanisms contributing to EGIDs. As such, anti-IgE therapy was used to treat eight patients with EGIDs. A 16-week trial of omalizumab resulted in no impact on T-cell proliferation, antigen dose responses, precursor frequency, or cytokine expression [75]. These findings do not support a direct role for IgE in EGIDs.

Eosinophils express a number of cytokine receptors, including those associated with remodeling and fibrosis: IL-13, TGF- β , and tumor necrosis factor (TNF). Eosinophils can respond differently to their microenvironment, inducing expression of either Th1 or Th2-associated chemokines and, thus, may play a role in orchestration of the immune milieu in EGIDs.

Numerous histological studies have described increased eosinophil presence in intestinal mucosal biopsies. In addition, granule proteins have been detected in colonic perfusion fluids and stool samples from patients with intestinal inflammation. Thus, eosinophils are present and secrete their granule contents.

However, the role and function of the eosinophil in intestinal inflammation remains unclear. Eosinophils while containing an armamentarium of molecules shown to elicit dysfunctional effects in other organs, particularly the lung, have not yet been examined in detail in the intestines. In this regard, immunohistochemical assessment of human tissues affected by inflammatory bowel diseases demonstrates increased staining for EPX suggesting a potential role for eosinophil activation in these diseases (Fig. 2). Further basic and translational

investigations are necessary in this area to provide insights into eosinophil response to tissue microenvironments, mechanisms contributing to pathology and descriptions of patient/disease phenotypes, and may lead to novel targeted therapeutic options for these EGIDs.

Conclusion

In summary, eosinophils continue to be enigmatic cells that likely serve a role in health and disease. Eosinophil enumeration continues to be the gold standard for fulfilling the histological diagnostic parameter, but future studies will characterize other meaningful criteria that may not only include histology, but also molecular parameters. Functional studies of EGIDs are lacking and much needed to understand the physiological and pathophysiological roles of eosinophils in the gastrointestinal tract. Because of the overall rarity and mechanistic overlaps of EGIDs, collaborative, multidisciplinary studies will provide the most rapid and meaningful discoveries.

Acknowledgments

The authors are grateful to Cheryl Protheroe, Lindsay Hosford, Joe Ruybal, and Kelly Capocelli for their expertise in tissue immunohistochemical staining and analysis. This work was funded in part by the Division of Intramural Research, NIAID, NIH. J.J.L. was supported by the Mayo Foundation and the NIH (HL065228).

References

1. Collins MH. Histopathology associated with eosinophilic gastrointestinal diseases. *Immunol Allergy Clin North Am.* 2009; 29:109–117. x–xi. ExternalResolverBasic Bibliographic Links. [PubMed: 19141346]
2. Spergel JM, Book WM, Mays E, et al. Variation in prevalence, diagnostic criteria, and initial management options for eosinophilic gastrointestinal diseases in the United States. *J Pediatr Gastroenterol Nutr.* 2011; 52:300–306. Ovid Full Text ExternalResolverBasic Bibliographic Links. Multidisciplinary group and advocacy teamed to identify the highly variable pattern of diagnostic approaches of healthcare providers. It emphasizes need for well publicized consensus recommendations. [PubMed: 21057327]
3. Doyle LA, Odze RD. Eosinophilic esophagitis without abundant eosinophils? The expanding spectrum of a disease that is difficult to define. *Dig Dis Sci.* 2011; 56:1923–1925. ExternalResolverBasic Bibliographic Links. [PubMed: 21533612]
4. Foroutan M, Norouzi A, Molaei M, et al. Eosinophilic esophagitis in patients with refractory gastroesophageal reflux disease. *Dig Dis Sci.* 2010; 55:28–31. Ovid Full Text ExternalResolverBasic Bibliographic Links. [PubMed: 19241170]
5. Kanakala V, Lamb CA, Haigh C, et al. The diagnosis of primary eosinophilic oesophagitis in adults: missed or misinterpreted? *Eur J Gastroenterol Hepatol.* 2010; 22:848–855. [PubMed: 20453656]
6. Odze RD. Pathology of eosinophilic esophagitis: what the clinician needs to know. *Am J Gastroenterol.* 2009; 104:485–490. ExternalResolverBasic Bibliographic Links. [PubMed: 19174804]
7. Patel N, Busler JF, Geisinger K, Hill I. Are pathologists accurately diagnosing eosinophilic esophagitis in children? A 9-year single academic institutional experience with interobserver observations. *Int J Surg Pathol.* 2011; 19:290–296. ExternalResolverBasic Bibliographic Links. [PubMed: 20484141]
8. Lowichik A, Weinberg A. A quantitative evaluation of mucosal eosinophils in the pediatric gastrointestinal tract. *Mod Pathol.* 1996; 9:110–114. ExternalResolverBasic Bibliographic Links. [PubMed: 8657715]
9. DeBrosse CW, Case JW, Putnam PE, et al. Quantity and distribution of eosinophils in the gastrointestinal tract of children. *Pediatr Dev Pathol.* 2006; 9:210–218. ExternalResolverBasic Bibliographic Links. [PubMed: 16944979]
10. Kalach N, Huvenne H, Gosset P, et al. Eosinophil counts in upper digestive mucosa of western European children: variations with age, organs, symptoms, *Helicobacter pylori* status, and

- pathological findings. *J Pediatr Gastroenterol Nutr.* 2011; 52:175–182. Ovid Full Text ExternalResolverBasic Bibliographic Links. [PubMed: 20890222]
11. Lwin T, Melton SD, Genta RM. Eosinophilic gastritis: histopathological characterization and quantification of the normal gastric eosinophil content. *Mod Pathol.* 2011; 24:556–563. ExternalResolverBasic Bibliographic Links. [PubMed: 21169993]
 12. Pensabene L, Brundler MA, Bank JM, Di Lorenzo C. Evaluation of mucosal eosinophils in the pediatric colon. *Dig Dis Sci.* 2005; 50:221–229. Ovid Full Text ExternalResolverBasic Bibliographic Links. [PubMed: 15745076]
 13. Saad A. Normal quantity and distribution of mast cells and eosinophils in the pediatric colon. *Pediatr Dev Pathol.* 2011
 14. Bonis PA. Putting the puzzle together: epidemiological and clinical clues in the etiology of eosinophilic esophagitis. *Immunol Allergy Clin North Am.* 2009; 29:41–52. viii. ExternalResolverBasic Bibliographic Links. [PubMed: 19141340]
 15. Kaijser R. To the attention of allergic affections of the digestive tract, from the standpoint of the surgeon. *Arch Klin Chir.* 1937; 188:36–64.
 16. Klein NC, Hargrove RL, Sleisenger MH, Jeffries GH. Eosinophilic gastroenteritis. *Medicine (Baltimore).* 1970; 49:299–319. [PubMed: 5426746]
 17. Rothenberg ME. Eosinophilic gastrointestinal disorders (EGID). *J Allergy Clin Immunol.* 2004; 113:11–28. quiz 29. [PubMed: 14713902]
 18. Fleischer DM, Atkins D. Evaluation of the patient with suspected eosinophilic gastrointestinal disease. *Immunol Allergy Clin North Am.* 2009; 29:53–63. ix. [PubMed: 19141341]
 19. Hurtado CW, Furuta GT, Kramer RE. Etiology of esophageal food impactions in children. *J Pediatr Gastroenterol Nutr.* 2011; 52:43–46. Ovid Full Text ExternalResolverBasic Bibliographic Links. [PubMed: 20975581]
 20. Furuta GT, Liacouras CA, Collins MH, et al. Eosinophilic esophagitis in children and adults: a systematic review and consensus recommendations for diagnosis and treatment. *Gastroenterology.* 2007; 133:1342–1363. ExternalResolverBasic Bibliographic Links. [PubMed: 17919504]
 21. Liacouras CA, Furuta GT, Hirano I, et al. Eosinophilic esophagitis: updated consensus recommendations for children and adults. *J Allergy Clin Immunol.* 2011; 128:3.e6–20.e6. Multidisciplinary report highlighting newest developments in EoE emphasizing chronicity of disease, variability in phenotypic patterns, and necessity for well designed clinical and translational investigations. [PubMed: 21477849]
 22. Garcia-Compean D, Gonzalez Gonzalez JA, Marrufo Garcia CA, et al. Prevalence of eosinophilic esophagitis in patients with refractory gastroesophageal reflux disease symptoms: a prospective study. *Dig Liver Dis.* 2011; 43:204–208. ExternalResolverBasic Bibliographic Links. [PubMed: 20843755]
 23. Hasosah MY, Sukkar GA, Alshafi AF, et al. Eosinophilic esophagitis in Saudi children: symptoms, histology and endoscopy results. *Saudi J Gastroenterol.* 2011; 17:119–123. ExternalResolverBasic Bibliographic Links. [PubMed: 21372349]
 24. Abe Y, Iijima K, Ohara S, et al. A Japanese case series of 12 patients with esophageal eosinophilia. *J Gastroenterol.* 2011; 46:25–30. ExternalResolverBasic Bibliographic Links. [PubMed: 20686904]
 25. Vindigni C, Villanacci V, Marini M, et al. Eosinophilic esophagitis: an Italian experience. *Rev Esp Enferm Dig.* 2010; 102:15–19. ExternalResolverBasic Full Text Bibliographic Links. [PubMed: 20187680]
 26. Aceves SS, Chen D, Newbury RO, et al. Mast cells infiltrate the esophageal smooth muscle in patients with eosinophilic esophagitis, express TGF-beta1, and increase esophageal smooth muscle contraction. *J Allergy Clin Immunol.* 2010; 126:1198–1204. e1194. ExternalResolverBasic Bibliographic Links. First translational study to assess and demonstrate a functional impact in EoE using an ex-vivo system. Mechanistic impact of mast cells in this process is also demonstrated in this article. [PubMed: 21047675]
 27. Basseri B, Levy M, Wang HL, et al. Redefining the role of lymphocytes in gastroesophageal reflux disease and eosinophilic esophagitis. *Dis Esophagus.* 2010; 23:368–376. ExternalResolverBasic. [PubMed: 20353445]

28. Lee S, de Boer WB, Naran A, et al. More than just counting eosinophils: proximal oesophageal involvement and subepithelial sclerosis are major diagnostic criteria for eosinophilic oesophagitis. *J Clin Pathol.* 2010; 63:644–647. ExternalResolverBasic Bibliographic Links. [PubMed: 20591916]
29. Mulder DJ, Justinich CJ. B cells, IgE and mechanisms of type I hypersensitivity in eosinophilic oesophagitis. *Gut.* 2010; 59:6–7. ExternalResolverBasic Bibliographic Links. [PubMed: 20007954]
30. Vicario M, Blanchard C, Stringer KF, et al. Local B cells and IgE production in the oesophageal mucosa in eosinophilic oesophagitis. *Gut.* 2010; 59:12–20. ExternalResolverBasic Bibliographic Links. [PubMed: 19528036]
31. Dellon ES, Chen X, Miller CR, et al. Tryptase staining of mast cells may differentiate eosinophilic esophagitis from gastroesophageal reflux disease. *Am J Gastroenterol.* 2011; 106:264–271. ExternalResolverBasic Bibliographic Links. Translational study identifying potential role of tryptase staining as a tool to distinguish between commonly confused diseases. [PubMed: 20978486]
32. Li-Kim-Moy JP, Tobias V, Day AS, et al. Esophageal subepithelial fibrosis and hyalinization are features of eosinophilic esophagitis. *J Pediatr Gastroenterol Nutr.* 2011; 52:147–153. Ovid Full Text ExternalResolverBasic Bibliographic Links. [PubMed: 21206380]
33. Kephart GM, Alexander JA, Arora AS, et al. Marked deposition of eosinophil-derived neurotoxin in adult patients with eosinophilic esophagitis. *Am J Gastroenterol.* 2010; 105:298–307. ExternalResolverBasic Bibliographic Links. [PubMed: 19888203]
34. Mueller S, Aigner T, Neureiter D, Stolte M. Eosinophil infiltration and degranulation in oesophageal mucosa from adult patients with eosinophilic oesophagitis: a retrospective and comparative study on pathological biopsy. *J Clin Pathol.* 2006; 59:1175–1180. Ovid Full Text ExternalResolverBasic Bibliographic Links. [PubMed: 16556666]
35. Mueller S, Neureiter D, Aigner T, Stolte M. Comparison of histological parameters for the diagnosis of eosinophilic oesophagitis versus gastro-oesophageal reflux disease on oesophageal biopsy material. *Histopathology.* 2008; 53:676–684. ExternalResolverBasic Bibliographic Links. [PubMed: 19076684]
36. Protheroe C, Woodruff SA, de Petris G, et al. A novel histologic scoring system to evaluate mucosal biopsies from patients with eosinophilic esophagitis. *Clin Gastroenterol Hepatol.* 2009; 7:749–755. e711. ExternalResolverBasic Bibliographic Links. [PubMed: 19345285]
37. Chang JY, Choung RS, Lee RM, et al. A shift in the clinical spectrum of eosinophilic gastroenteritis toward the mucosal disease type. *Clin Gastroenterol Hepatol.* 2010; 8:669–675. quiz e688. [PubMed: 20451664]
38. Talley NJ, Shorter RG, Phillips SF, Zinsmeister AR. Eosinophilic gastroenteritis: a clinicopathological study of patients with disease of the mucosa, muscle layer, and subserosal tissues. *Gut.* 1990; 31:54–58. ExternalResolverBasic Bibliographic Links. [PubMed: 2318432]
39. Dohil R, Newbury R, Fox L, et al. Oral viscous budesonide is effective in children with eosinophilic esophagitis in a randomized, placebo-controlled trial. *Gastroenterology.* 2010; 139:418–429. Clinical study identifying positive impact of novel form of topical steroid in children with EoE. [PubMed: 20457157]
40. Straumann A, Conus S, Degen L, et al. Long-term budesonide maintenance treatment is partially effective for patients with eosinophilic esophagitis. *Clin Gastroenterol Hepatol.* 2011; 9:400.e1, 409.e1. First study identifying positive and safe impact of chronic use of topical steroids in adults. [PubMed: 21277394]
41. Dellon ES, Gibbs WB, Rubinas TC, et al. Esophageal dilation in eosinophilic esophagitis: safety and predictors of clinical response and complications. *Gastrointest Endosc.* 2010; 71:706–712. ExternalResolverBasic Bibliographic Links. [PubMed: 20170913]
42. Hirano I. Dilation in eosinophilic esophagitis: to do or not to do? *Gastrointest Endosc.* 2010; 71:713–714. [PubMed: 20363413]
43. Schoepfer AM, Gonsalves N, Bussmann C, et al. Esophageal dilation in eosinophilic esophagitis: effectiveness, safety, and impact on the underlying inflammation. *Am J Gastroenterol.* 2010; 105:1062–1070. ExternalResolverBasic Bibliographic Links. [PubMed: 19935783]

44. Jung KW, Gundersen N, Kopacova J, et al. Occurrence of and risk factors for complications after endoscopic dilation in eosinophilic esophagitis. *Gastrointest Endosc.* 2011; 73:15–21. ExternalResolverBasic Bibliographic Links. [PubMed: 21067739]
45. Rothenberg ME, Mishra A, Brandt EB, Hogan SP. Gastrointestinal eosinophils in health and disease. *Adv Immunol.* 2001; 78:291–328. ExternalResolverBasic Bibliographic Links. [PubMed: 11432207]
46. Sanderson CJ. Eosinophil differentiation factor (interleukin-5). *Immunol Ser.* 1990; 49:231–256. ExternalResolverBasic Bibliographic Links. [PubMed: 2090253]
47. Frick WE, Sedgwick JB, Busse WW. The appearance of hypodense eosinophils in antigen-dependent late phase asthma. *Am Rev Respir Dis.* 1989; 139:1401–1406. ExternalResolverBasic Bibliographic Links. [PubMed: 2729749]
48. Fukuda T, Dunnette SL, Reed CE, et al. Increased numbers of hypodense eosinophils in the blood of patients with bronchial asthma. *Am Rev Respir Dis.* 1985; 132:981–985. ExternalResolverBasic Bibliographic Links. [PubMed: 4062053]
49. Bruijnzeel PL, Rihs S, Virchow JC Jr, et al. Early activation or ‘priming’ of eosinophils in asthma. *Schweiz Med Wochenschr.* 1992; 122:298–301. ExternalResolverBasic Bibliographic Links. [PubMed: 1546279]
50. Dri P, Cramer R, Spessotto P, et al. Eosinophil activation on biologic surfaces. Production of O₂-in response to physiologic soluble stimuli is differentially modulated by extracellular matrix components and endothelial cells. *J Immunol.* 1991; 147:613–620. [PubMed: 1712813]
51. Tai PC, Spry CJ, Peterson C, et al. Monoclonal antibodies distinguish between storage and secreted forms of eosinophil cationic protein. *Nature.* 1984; 309:182–184. [PubMed: 6717597]
52. Young JD, Peterson CG, Venge P, Cohn ZA. Mechanism of membrane damage mediated by human eosinophil cationic protein. *Nature.* 1986; 321:613–616. ExternalResolverBasic Bibliographic Links. [PubMed: 2423882]
53. Yousefi S, Gold JA, Andina N, et al. Catapult-like release of mitochondrial DNA by eosinophils contributes to antibacterial defense. *Nat Med.* 2008; 14:949–953. ExternalResolverBasic Bibliographic Links. [PubMed: 18690244]
54. Lee JJ, Jacobsen EA, McGarry MP, et al. Eosinophils in health and disease: the LIAR hypothesis. *Clin Exp Allergy.* 2010; 40:563–575. ExternalResolverBasic Bibliographic Links. [PubMed: 20447076]
55. Rothenberg ME. Biology and treatment of eosinophilic esophagitis. *Gastroenterology.* 2009; 137:1238–1249. ExternalResolverBasic Bibliographic Links. [PubMed: 19596009]
56. Blanchard C, Stucke EM, Burwinkel K, et al. Coordinate interaction between IL-13 and epithelial differentiation cluster genes in eosinophilic esophagitis. *J Immunol.* 2010; 184:4033–4041. ExternalResolverBasic Bibliographic Links. Identification of novel genes that may participate in the pathogenesis of EoE including filaggrin, a barrier altering gene that is critical in the development of eczema. [PubMed: 20208004]
57. Caldwell JM, Blanchard C, Collins MH, et al. Glucocorticoid-regulated genes in eosinophilic esophagitis: a role for FKBP51. *J Allergy Clin Immunol.* 2010; 125:879–888. e878. ExternalResolverBasic Bibliographic Links. [PubMed: 20371398]
58. Rothenberg ME, Spergel JM, Sherrill JD, et al. Common variants at 5q22 associate with pediatric eosinophilic esophagitis. *Nat Genet.* 2010; 42:289–291. ExternalResolverBasic Bibliographic Links. Identification of gene variant and tissue overexpression of TSLP in children with EoE. [PubMed: 20208534]
59. Sherrill JD, Gao PS, Stucke EM, et al. Variants of thymic stromal lymphopoietin and its receptor associate with eosinophilic esophagitis. *J Allergy Clin Immunol.* 2010; 126:160–165. e163. ExternalResolverBasic Bibliographic Links. [PubMed: 20620568]
60. Tantibhaedhyangkul U, Tatevian N, Gilger MA, et al. Increased esophageal regulatory T cells and eosinophil characteristics in children with eosinophilic esophagitis and gastroesophageal reflux disease. *Ann Clin Lab Sci.* 2009; 39:99–107. ExternalResolverBasic Bibliographic Links. [PubMed: 19429794]

61. Fuentebella J, Patel A, Nguyen T, et al. Increased number of regulatory T cells in children with eosinophilic esophagitis. *J Pediatr Gastroenterol Nutr.* 2010; 51:283–289. Ovid Full Text ExternalResolverBasic Bibliographic Links. [PubMed: 20639775]
62. Stuck MC, Straumann A, Simon HU. Relative lack of T regulatory cells in adult eosinophilic esophagitis: no normalization after corticosteroid therapy. *Allergy.* 2011; 66:705–707. ExternalResolverBasic Bibliographic Links. [PubMed: 21470243]
63. Mulder DJ, Pooni A, Mak N, et al. Antigen presentation and MHC class II expression by human esophageal epithelial cells: role in eosinophilic esophagitis. *Am J Pathol.* 2011; 178:744–753. ExternalResolverBasic Bibliographic Links. [PubMed: 21281807]
64. Hsu Blatman KS, Gonsalves N, Hirano I, Bryce PJ. Expression of mast cell-associated genes is upregulated in adult eosinophilic esophagitis and responds to steroid or dietary therapy. *J Allergy Clin Immunol.* 2011; 127:1307.e3–1308e3. ExternalResolverBasic. [PubMed: 21333344]
65. Huang JJ, Joh JW, Fuentebella J, et al. Eotaxin and FGF enhance signaling through an extracellular signal-related kinase (ERK)-dependent pathway in the pathogenesis of eosinophilic esophagitis. *Allergy Asthma Clin Immunol.* 2010; 6:25. ExternalResolverBasic. [PubMed: 20815913]
66. Blanchard C, Stucke EM, Rodriguez-Jimenez B, et al. A striking local esophageal cytokine expression profile in eosinophilic esophagitis. *J Allergy Clin Immunol.* 2011; 127:208–217. ExternalResolverBasic Bibliographic Links. [PubMed: 21211656]
67. Zhu X, Wang M, Mavi P, et al. Interleukin-15 expression is increased in human eosinophilic esophagitis and mediates pathogenesis in mice. *Gastroenterology.* 2010; 139:182–193. e187. ExternalResolverBasic Bibliographic Links. [PubMed: 20381491]
68. Zuo L, Fulkerson PC, Finkelman FD, et al. IL-13 induces esophageal remodeling and gene expression by an eosinophil-independent, IL-13R alpha2-inhibited pathway. *J Immunol.* 2010; 185:660–669. ExternalResolverBasic Bibliographic Links. [PubMed: 20543112]
69. Roman S, Hirano I, Kwiatek MA, et al. Manometric features of eosinophilic esophagitis in esophageal pressure topography. *Neurogastroenterol Motil.* 2011; 23:208–214. e111. ExternalResolverBasic Bibliographic Links. [PubMed: 21091849]
70. Waddell A, Ahrens R, Steinbrecher K, et al. Colonic eosinophilic inflammation in experimental colitis is mediated by Ly6C(high) CCR2(+) inflammatory monocyte/macrophage-derived CCL11. *J Immunol.* 2011; 186:5993–6003. This study was based on association of the inflammatory bowel diseases susceptibility loci 17q12 with the chemokine, CCL11. Investigators determine the critical role of specific macrophage population, Ly6C(high) CCR2(+) inflammatory, in the generation of murine colitis, a finding not previously reported. [PubMed: 21498668]
71. Furuta GT, Nieuwenhuis EE, Karhausen J, et al. Eosinophils alter colonic epithelial barrier function: role for major basic protein. *Am J Physiol Gastrointest Liver Physiol.* 2005; 289:G890–897. ExternalResolverBasic Bibliographic Links. [PubMed: 16227527]
72. Forbes E, Murase T, Yang M, et al. Immunopathogenesis of experimental ulcerative colitis is mediated by eosinophil peroxidase. *J Immunol.* 2004; 172:5664–5675. ExternalResolverBasic Bibliographic Links. [PubMed: 15100311]
73. McNamee EN, Wermers JD, Masterson JC, et al. Novel model of TH2-polarized chronic ileitis: the SAMP1 mouse. *Inflamm Bowel Dis.* 2010; 16:743–752. Ovid Full Text ExternalResolverBasic Bibliographic Links. [PubMed: 19856411]
74. Masterson JC, McNamee EN, Jedlicka P, et al. CCR3 antibody blockade attenuates eosinophilic ileitis and associated remodeling. *Am J Pathol.* (in press).
75. Foster B, Foroughi S, Yin Y, Prussin C. Effect of anti-IgE therapy on food allergen specific T cell responses in eosinophil associated gastrointestinal disorders. *Clin Mol Allergy.* 2011; 9:7. ExternalResolverBasic. [PubMed: 21527026]

Key Points

- The normal number of eosinophils in the stomach, small intestine, and colon continues to undergo definition and may be influenced by a number of different factors
- Eosinophilic inflammation of the gastrointestinal tract is a nonspecific finding.
- Eosinophilic gastrointestinal diseases (EGIDs) are characterized by common gastrointestinal symptoms and eosinophil predominant inflammation. Other causes for symptoms and inflammation should be ruled out before assigning a diagnosis of EGIDs.
- Basic studies identify pathogenetic roles for eosinophils in murine models of colitis and intestinal remodeling.

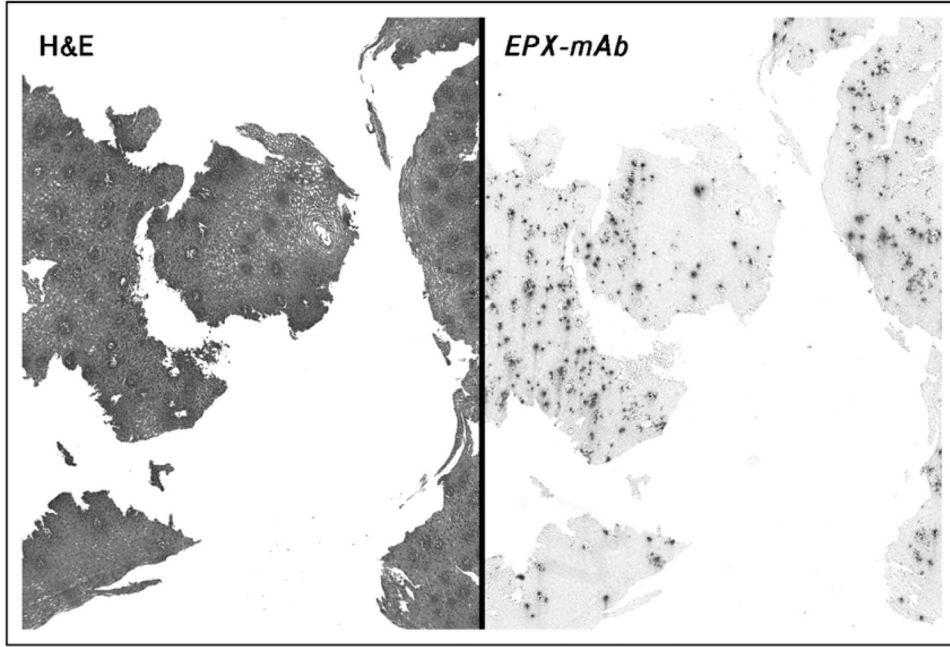


Figure 1. Eosinophils in eosinophilic esophagitis

Hematoxylin and eosin and eosinophil peroxidase staining of the esophageal tissue from a patient with eosinophilic esophagitis (EoE). EPX antibody (Clone: MM25-82-2) was used to stain a section from a patient with EoE. EPX (black dots) staining is evident in the squamous epithelia that is not easily evident in the hematoxylin and eosin stained tissue.

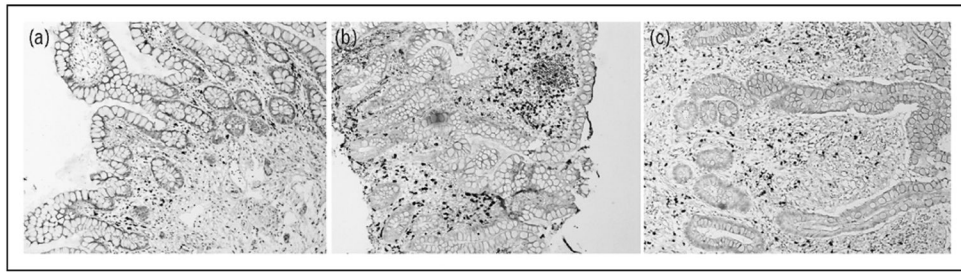


Figure 2. Eosinophil peroxidase staining of ileal tissue from patients with Crohn's disease
EPX antibody (Clone: MM25-82.2) was used to stain mucosal biopsy and resection tissue from children with (a) no evidence of inflammatory disease (b) Chron's disease untreated, and (c) Chrons's disease following steroid treatment. EPX (black dots) staining is evident in the lamina propria. Reduced eosinophil numbers were observed following treatment.

Table 1

Differential diagnoses for intestinal eosinophilia

Esophageal	Small intestinal and colonic
Gastroesophageal reflux disease	Food hypersensitivity
Eosinophilic esophagitis	Eosinophilic gastrointestinal disease
Eosinophilic gastroenteritis	Crohn's disease
Celiac	Ulcerative colitis
Crohn's disease	Celiac disease
Achalasia	Churg-Strauss Syndrome
Connective tissue disease	Systemic lupus erythematosus
Hypereosinophilic syndrome	Infections: <i>Ancylostoma duodenale</i> , <i>Anisakiasis</i> , <i>Basidiobolomycosis</i> , <i>Enterobius vermicularis</i> , <i>Helicobacter pylori</i> , <i>Schistosomiasis</i> , <i>Toxocara canis</i>
Infectious: <i>Candida</i> , Herpes virus	Malignancy
Drug hypersensitivity response	
Vasculitis	
Pemphigoid vegetans	
Graft-versus-host disease	
Other causes of Chronic vomiting (Arnold-Chiari malformations, gastric dysmotility, etc.)	

Table 2**2 Changes to original eosinophilic esophagitis consensus recommendations**

Abbreviation change from 'EE' to 'EoE'	The acronym EE is confused with erosive esophagitis, thus the change to EoE
Use of word 'chronic'	Increasing experience and studies identify EoE as a chronic disease requiring long-term follow-up and management
Use of terms 'immune/antigen-driven'	Clinical, translational, and basic studies identify potential aberrant immune response as pathogenetic features of EoE
Some patients with EoE may present with less than 15 eosinophils/HPF	A small numbers of patients with EoE might have less than the threshold number of eosinophils. Potential reasons for this include inadequate biopsy specimen number, sampling error, longstanding chronic disease that resulted in remodeled tissue, or partial treatment response to use of other topical steroids for concomitant nasal or respiratory allergies
Introduction of term 'pump inhibitor (PPI)-responsive esophageal eosinophilia'	PPIs may have anti-inflammatory or barrier-healing properties that contribute to resolution of esophageal eosinophilia

EoE, eosinophilic esophagitis; HPF, high power field. Modified from [21*].