

IMAGE GUIDANCE IN NEUROSURGICAL PROCEDURES, THE “VISAGES” POINT OF VIEW

C. Barillot, P. Coupé, O. El Ganaoui, B. Gibaud, P. Hellier, P. Jannin, P. Paul, S. Prima, N. Wiest-Daesslé, X. Morandi*

INSERM U746, VisAGeS Unit/Project, Campus de Beaulieu, 35042 Rennes Cx, France
INRIA, VisAGeS Unit/Project, IRISA, Campus de Beaulieu, 35042 Rennes Cx, France
University of Rennes I, UMR CNRS 6074, IRISA, Campus de Beaulieu, 35042 Rennes Cx, France
*CHU Rennes, rue H. le Guillou, 35043 Rennes Cx, France

ABSTRACT

This paper gives an overview of the evolution of clinical neuroinformatics in the domain of neurosurgery. It shows how image guided neurosurgery (IGNS) is evolving according to the integration of new imaging modalities before, during and after the surgical procedure and how this acts as the premise of the Operative Room of the future. These different issues, as addressed by the VisAGeS INRIA/INSERM U746 research team (<http://www.irisa.fr/visages>), are presented and discussed in order to exhibit the benefits of an integrated work between physicians (radiologists, neurologists and neurosurgeons) and computer scientists to give adequate answers toward a more effective use of images in IGNS.

Index Terms— Medical Imaging, Image Guided Neuro-Surgery, Intraoperative Ultrasound, Magnetic Resonance Imaging, Diffusion Tensor Imaging, Image Registration, Surgical Workflows

1. INTRODUCTION

In the last decade, it has become increasingly common to use image-guided navigation systems to assist surgical procedures with medical images. Benefits have been reported for accuracy improvement, reduction of intervention time, improvement of quality of life, reduction of morbidity (and perhaps mortality), reduction of intensive care and hospital costs. Image-guided systems are used today to help the surgeon to plan the surgery and provide accurate information about anatomy and function during the intervention. Image-guided systems also enable minimally invasive interventions, since the intraoperative images can be used interactively as a guide.

Image guided neurosurgical procedures rely on complex preoperative planning and intraoperative environment. This includes various multimodal examinations: anatomical, vascular, functional explorations and an increasing number of computer-assisted systems taking place in the Operating Room. Hereto, using an image-guided surgery system, a rigid fusion between the patient's head and the preoperative data is preformed. With an optical tracking system and Light Emitting Diodes (LED), it is possible to track the patient's head, the microscope and the surgical instruments

in real time (Fig. 1). The preoperative data can then be merged with the surgical field of view displayed in the microscope. This fusion is called “augmented reality”.

Unfortunately, the assumption of a rigid registration between the patient's head and the preoperative images only holds at the beginning of the procedure as soft tissues tend to deform during the intervention. This is a common problem in many image-guided interventions, the particular case of neurosurgical procedures can be considered as a representative case. Brain shift is one manifestation of this problem but other tissue deformations can occur and must be taken into account for a more realistic predictive work.

To do so, one can perform biomechanical modeling of brain tissue deformation according to the prediction of occurring forces during surgery (e.g. [1]). Another possibility is to deform the anatomical and functional images according to the estimated deformation. Hereto, intraoperative imaging is required. Whereas intraoperative MR has been used for image guided neurosurgery, this is a high cost and rather bulky solution [2-4]. Recently, 3D ultrasound (3DUS) was introduced as a possible intraoperative modality for neurosurgery [5-10]. This modality hardly affects the operating room logistics and is therefore easily accepted by the neurosurgeons. First results have shown the capacity of 3D intraoperative ultrasound to compensate for brain shift [11, 12].

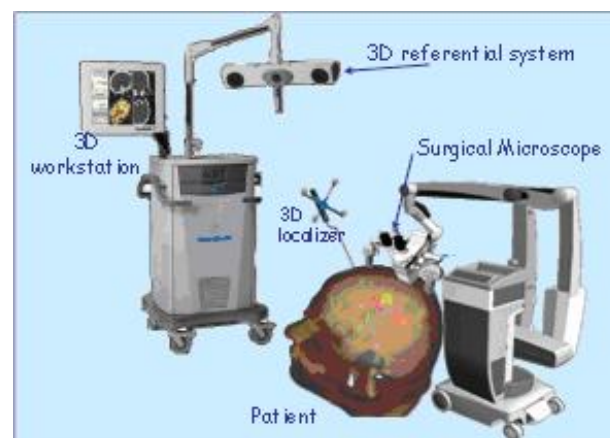


Fig. 1: Principle of Image guided neurosurgical procedures using a neuronavigation system

2. IMAGE GUIDANCE IN PRE-OPERATIVE NEUROSURGICAL PROCEDURES

The follow-up of a patient who undergoes a neurosurgical procedure is an illustrative example of the complexity of the medical decision process. This complexity is related in particular to the heterogeneity of the data produced at different stages of the clinical follow-up. The emergence of new neuroimaging techniques has widely modified the way this issue can be addressed. To delineate the surgical zone, different sources of information are used today and a congruence of several explorations is needed to better delineate the anatomical and functional vicinity of the surgical target.

2.1 Delineation of cortical anatomical landmarks

This problem concerns both assisting the surgeon in the identification of gyri and sulci in MRI images (image segmentation and analysis), and delineating a local cortical roadmap to the surgical target. The detection and display of complex anatomical structures such as cortical gyri or sulci is complex ([13, 14]). These structures have no explicit representation on the image data. Nonetheless, it is from their representation on images (i.e. MRI) that the surgeon can improve his surgical strategy. In practice, the sulci were considered very useful, either because they provided information about the border of the planned resection, or an access to the lesion (trans-sulcal approach), or simply because they provided interesting anatomical landmarks. The joint use of these various data plays a key role for the preparation of the adapted roadmap to surgery for each patient [15]. More than 120 patients have followed this procedure in Rennes in the last 5 years.

2.2 Delineation of white matter fibers bundles

For the purpose of integrating white matter markers in the pre-surgical workflow, we have developed a general purpose application implementing most of the state-of-the-art methods for diffusion-weighted (DW) and Diffusion Tensor (DT) MRI. Experiments have been performed on patients with brain tumors (e.g. low grade gliomas). As expected, changes in the direction of fibers and the relations between the fibers bundles and the tumor shapes were revealed, additional studies are currently under investigation to validate these outcomes on various lesion grades and especially to better correlate functional observations (e.g. from fMRI) with the fibers bundles (e.g. [16, 17]).

2.3 Delineation of functional landmarks

To better understand the functional behavior of the healthy tissue, functional and metabolic imaging is required. Some imaging modalities are static (e.g. MRI), and some may reflect the spatio-temporal dynamics of the brain pathology. Integration of multimodal information about brain perfusion (SPECT), metabolism (PET-F¹⁸FDG), anatomy (MRI, DTI),

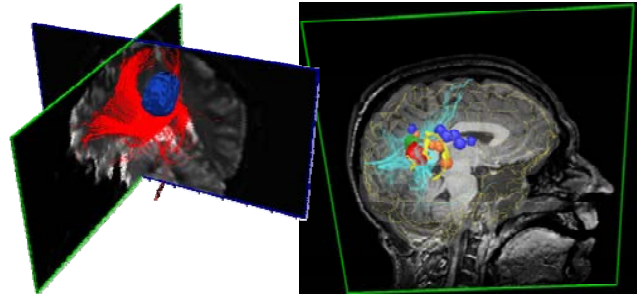


Fig. 2: Combination of multimodal pre-surgical data outlining low grade lesions surrounded by fibers bundles (right: with fMRI markers as balls and sulci ribbons).

as well as direct recording of functional activity (MEG/EEG or fMRI), improves significantly on its own the way patients are explored (e.g. [18-20]). The current evolution is to use synchronous fMRI/EEG in functional neurosurgery and more generally Tensor Diffusion Imaging or molecular imaging [21-24] to better address all scales of analysis of the brain tissues in order to define the best roadmap as possible to the surgical target while keeping the eloquent tissue safe.

2.4 Integration of the roadmap to surgery

Once all anatomical and functional markers are being extracted from the different image sequences, they are registered within a single patient referential thru intensity based registration procedures [25, 26]. Fig. 2 illustrates examples of fusion of anatomical and functional markers for the definition of the surgical roadmap; Fig. 3 illustrates how the markers are integrated within the oculars of the surgical microscope as 2D monochromatic contours.

3. IMAGE GUIDANCE IN INTRAOPERATIVE NEUROSURGICAL PROCEDURES

As said in the introduction, the assumption of a rigid registration between the patient's head and the preoperative images does not stand when brain surgery starts. New observations have to be introduced in order to update the pre-surgical roadmap. To do so, both video images and ultrasound images can be captured to image the tissue motion. The first observation is relevant to better measure the evolution of the cortical surface up to the resection. The second one is more relevant to update the position of the lesion borders inside the brain.

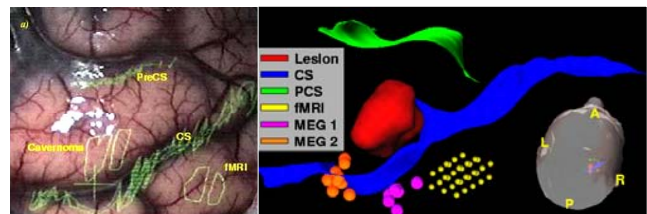


Fig. 3: Pre-surgical roadmap (right) with the corresponding mapping into the oculars of the surgical microscope (left).

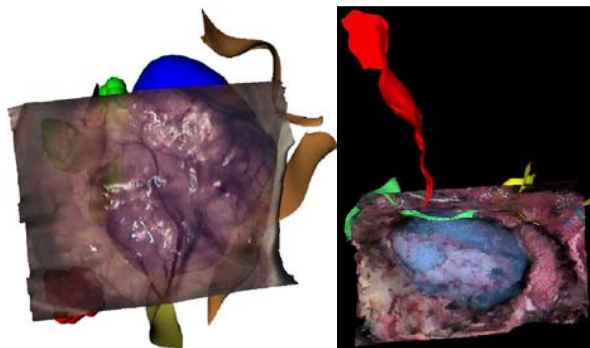


Fig. 4: Surface based intraoperative reconstruction after dura opening (right) and tumor resection (left).

3.1 Integration of surface-based intraoperative observations from video

2D monochromatic contours display to render the pre-surgical markers has shown some limitations. In order to improve the display of these pre operative images, we have introduced a new surface registration method using stereovision from stereoscopic images of the surgical microscope. It allows cheap, robust and reliable quantitative information about external surface deformations during surgery and robust computation of temporal deformation fields between brain surfaces [27, 28] (Fig. 4). This approach is limited to quantification of cortical surface deformations. However it provides an interesting real-time constraint for volumetric approach and a new augmented virtuality display mode.

3.2 Integration of intraoperative observations from volumetric ultrasound

To complement surface based representations, volumetric observations are required. We found that using 3D free hand ultrasound (3DUS) could be a realistic alternative to the rather bulky integration of intraoperative MRI. To integrate 3DUS, calibration, volumetric reconstruction and registration with preoperative data are required. 3D freehand ultrasound is a technique based on the acquisition of non-parallel B-scans, whose position in 3D space is known by a 3D localizer (optic or magnetic) attached to the probe. From these irregularly distributed B-scans and their positions, a regular 3D lattice volume has to be reconstructed. We have proposed a new 3D reconstruction method (TULIPE) that explicitly takes into account the 3D probe trajectory during intraoperative acquisition [29].

Then, 3D intraoperative ultrasound data have to be registered to preoperative MR images. This is still a challenging problem due to the difference of information contained in each image modality. To overcome this difficulty, we have introduced a new probabilistic function for similarity measurements based on the mean curvature of MR isophots and US hyperechogenic structures. First experiments were carried out showing that the proposed

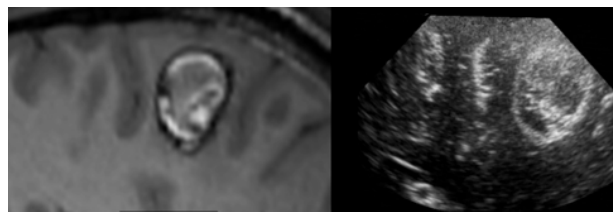


Fig. 5: Registration of intraoperative ultrasound with pre-operative MRI

method converges robustly compared to the standard registration techniques, with a computation time compatible with intraoperative use [30] (Fig. 5).

4. PERSPECTIVES

Additional sensors will shortly come in the operating room; among them are molecular data acquisitions or in-vivo 3D optical imaging and microscopy systems [31, 32]. Still the integration of these new intraoperative sensors is challenging. One of the most ambitious aspects concerns the problem of image fusion between the intra and pre-operative data, such as the mathematical modeling of matter dissipation during surgery. Other issues concern the temporal and scale resolutions of images which are not always adapted to the resection and the deformations that should be estimated. For instance, intraoperative data cannot be continuously acquired since this would interfere too much with the operative conditions. This implies to merge different observations gathered at different time and scales during surgery (typically, video, 3D ultrasound, in-vivo microscopy or molecular data). Finally, the way that all information will be integrated in a “transparent” way during surgery is still a challenging issue. One way is to integrate these various knowledges through the modeling of information sources for surgical planning.

Surgical planning relies on measures related to the patient, on explicit generic knowledge and on implicit knowledge resulting from the surgeons’ experience (e.g., learning period, clinical cases, discussion with colleagues, surgical literature). This last information is never formalized and is seldom used in computer aided surgical systems. One question of the future is to better understand how existing and additional surgical sensors and effectors can cohabit and be better integrated in the global surgical workflow. This issue is critical in order to *i)* make these systems accepted by surgeons, *ii)* speed up the learning phase of new practitioners, and *iii)* ensure at the end that information technology in surgery will improve the efficiency of the procedure by improving the cost-effectiveness of the added technology and also by reducing the morbidity and even the mortality. In this context, we have introduced a global methodology for modeling surgical procedures dealing with a domain ontology [33] used to describe the surgical procedures and extract surgical knowledge [34].

5. CONCLUSION

Nowadays, image guided surgical systems are actually available in a very large clinical context and they already participate to make the surgical practice safer and more efficient while trying to make these advanced tools still accessible to all citizens. Though the tasks of such systems are still evolving, the major challenges today are to design new computer assisted procedures to guide the clinician within the mass of information that he has to handle to take a decision, to perform the surgery and to better evaluate the efficiency of a treatment.

6. REFERENCES

- [1] M. I. Miga, *et al.*, "Model-Updated Image Guidance: Initial Clinical Experiences with Gravity-Induced Brain Deformation," *IEEE Trans Med Imaging*, vol. 18, pp. 866-74, 1999.
- [2] C. Nimsky, *et al.*, "Quantification of, visualization of, and compensation for brain shift using intraoperative magnetic resonance imaging," *Neurosurgery*, vol. 47, pp. 1070-9, 2000.
- [3] M. Ferrant, *et al.*, "Serial registration of intraoperative MR images of the brain," *Med Image Anal*, vol. 6, pp. 337-59, 2002.
- [4] C. R. Maurer, Jr., *et al.*, "Investigation of intraoperative brain deformation using a 1.5-T interventional MR system: preliminary results," *IEEE Trans Med Imaging*, vol. 17, pp. 817-25, 1998.
- [5] T. Arbel, *et al.*, "Automatic non-linear MRI-ultrasound registration for the correction of intraoperative brain deformations," *Comput Aided Surg*, vol. 9, pp. 123-36, 2004.
- [6] T. Ault and M. W. Siegel, "Frameless patient registration using ultrasonic imaging: a preliminary study," *J. Image Guided Surgery*, vol. 1, pp. 94-102., 1995.
- [7] R. D. Bucholz, *et al.*, "The correction of stereotactic inaccuracy caused by brain shift using an intraoperative ultrasound device," in *CVRMed-MRCAS, LNCS*, Springer-Verlag, Berlin-Heidelberg, 1997, pp. 459-66.
- [8] J. W. Trobaugh, *et al.*, "Frameless stereotactic ultrasonography: method and applications," *Comput Med Imaging Graph*, vol. 18, pp. 235-46, 1994.
- [9] R. M. Comeau, *et al.*, "Intraoperative ultrasound for guidance and tissue shift correction in image-guided neurosurgery," *Medical Physics*, vol. 27, pp. 787-800, 2000.
- [10] M. Makuuchi, *et al.*, "History of intraoperative ultrasound," *Ultrasound in Medicine and Biology*, vol. 24, pp. 1229-42, 1998.
- [11] M. Letteboer, *et al.*, "Acquisition of 3D ultrasound images during neuronavigation," *Proc. of CARS 2002*, Paris, France, 2002.
- [12] I. Pratikakis, *et al.*, "Robust multiscale deformable registration of 3D Ultrasound images," *International Journal of Image and Graphics*, vol. 3, pp. 547-66, 2003.
- [13] G. Le Goualher, *et al.*, "Three-dimensional segmentation and representation of cortical sulci using active ribbons," *Int. J. of Pattern Recognition and Artificial Intelligence*, vol. 11, pp. 1295-315, 1997.
- [14] G. Le Goualher, *et al.*, "Automated Extraction and Variability Analysis of Sulcal Neuroanatomy," *IEEE Trans Med Imaging*, vol. 18, pp. 206-17, 1999.
- [15] P. Jannin, *et al.*, "Integration of sulcal and functional information for multimodal neuronavigation," *Journal of Neurosurgery*, vol. 96, pp. 713-23, 2002.
- [16] C. Nimsky, *et al.*, "Preoperative and intraoperative diffusion tensor imaging-based fiber tracking in glioma surgery," *Neurosurgery*, vol. 56, pp. 130-8, 2005.
- [17] D. Merhof, *et al.*, "Fast and Accurate Connectivity Analysis Between Functional Regions Based on DT-MRI," in *MICCAI 2006*, LNCS-4191, Springer-Verlag, 2006, pp.225.
- [18] F. J. Rugg-Gunn, *et al.*, "Diffusion tensor imaging in refractory epilepsy," *Lancet*, vol. 359, pp. 1748-51, 2002.
- [19] M. Schreckenberger, *et al.*, "Localisation of motor areas in brain tumour patients: a comparison of preoperative [18 F] FDG-PET and intraoperative cortical electrostimulation," *European J. of Nucl. Med. and Mol Imaging*, vol. 28, pp. 1394-403, 2001.
- [20] M. P. Heilbrun, *et al.*, "Practical Application of fMRI for Surgical Planning," *Stereotactic and Functional Neurosurgery*, vol. 76, pp. 168-74, 2001.
- [21] R. Casse, *et al.*, "Positron emission tomography and epilepsy," *Mol Imaging Biol*, vol. 4, pp. 338-51, 2002.
- [22] R. Tummala, *et al.*, "Application of Diffusion Tensor Imaging to Magnetic-Resonance-Guided Brain Tumor Resection," *Pediatric Neurosurgery*, vol. 39, pp. 39-43, 2003.
- [23] S. Welschehold, *et al.*, "Evaluation of Fiber Tracking in Neurosurgery: 888," *Neurosurgery*, vol. 57, pp. 426, 2005.
- [24] C. S. Yu, *et al.*, "Diffusion tensor tractography in patients with cerebral tumors: a helpful technique for neurosurgical planning and postoperative assessment," *Eur J Radiol*, vol. 56, pp. 197-204, 2005.
- [25] C. Grova, *et al.*, "A methodology for generating normal and pathological brain perfusion SPECT images for evaluation of MRI/SPECT fusion methods: application in epilepsy," *Phys Med Biol*, vol. 48, pp. 4023-44, 2003.
- [26] N. Wiest-Daesslé, *et al.*, "Evaluation of a new optimisation algorithm for rigid registration of MRI data," *Proceedings of SPIE Medical Imaging 2007: Image Processing*, San Diego, USA, 2007.
- [27] P. Paul, *et al.*, "Augmented Virtuality Based on Stereoscopic Reconstruction in Multimodal Image-Guided Neurosurgery: Methods and Performance Evaluation," *IEEE Transactions on Medical Imaging*, vol. 24, pp. 1500, 2005.
- [28] P. Paul, *et al.*, "A surface registration approach for video-based analysis of intraoperative brain surface deformations," in: *AMI-ARC'06*, Copenhagen, DK, 2006.
- [29] P. Coupe, *et al.*, "3D Freehand Ultrasound Reconstruction Based on Probe Trajectory," in *MICCAI 2005*, vol. LNCS-3749, Palm Springs, CA, Springer-Verlag, 2005, pp. 597.
- [30] P. Coupé, *et al.*, "A Probabilistic Objective Function for 3d Rigid Registration of Intraoperative US and Preoperative MR Brain Images," *submitted to IEEE ISBI*, 2007.
- [31] M. A. Hunt, *et al.*, "Single-dose contrast agent for intraoperative MR imaging of intrinsic brain tumors by using ferumoxtran-10," *AJNR Am J Neuroradiol*, vol.26, pp. 1084-8, 2005.
- [32] M. Davenne, *et al.*, "In Vivo Imaging of Migrating Neurons in the Mammalian Forebrain," *Chem. Senses*, vol. 30, pp.115-6, 2005.
- [33] P. Jannin, *et al.*, "Models of surgical procedures for multimodal image-guided neurosurgery," *Computer Assisted Surgery*, vol. 8, pp. 98-106, 2003.
- [34] M. Raimbault, *et al.*, "Towards models of surgical procedures: analyzing a database of neurosurgical cases," *SPIE Medical Imaging 2005*, San Diego, CA, 2005.